

Research Article

Patterns and Clinical Presentation of Foreign Bodies in ENT among Sudanese Children in Khartoum State Hospitals

Dr. Rana Ahmed Abdelrahman Nasir¹, Sharfi Abdelgadir Omer Ahmed², and Dr. Ibrahim Gaffar Ibrahim³

¹MBBS Gezira University, Consultant ENT, Sudan

²Associate Prof. ORL Head and Neck Surgery, Faculty of Medicine and Health Sciences, Omdurman Islamic University, Sudan

³MBBS, MD ORL, Consultant ENT, Khartoum Sudan

Abstract

Background: Foreign bodies (FBs) in ENT are a common problem in Sudanese children and are associated with life threatening complications. **Objectives:** To study the patterns and presenting symptoms of children who are presented with foreign bodies Inhalation, Ingestion and insertion in the Nose and Ears. **Methodology:** This is a prospective hospital based descriptive study, conducted at Khartoum ENT Hospitals from March 2013 to January 2015. **Result:** 150 patients with foreign bodies were studied in Khartoum ENT Hospitals. The commonest age group between 3–6 years in 64% of patients. Male to Female ratio is 1.3:1. F.Bs nose constituted higher percentage in (28%) of cases, F.Bs inhalations were presented in (24.7%), F.Bs ear were presented in (24.7%) and F.Bs ingestion were presented in (22.7%). Regarding the type of inhalations, peanut was presented in (56.8%) of cases and the commonest presenting symptoms was cough in (94%) of patients. **Conclusion:** Certain food items especially peanuts if given to children below the age of 2 years have to be given with caution and under close supervision. Bronchoscopy should always be considered in optimum conditions. Public health education is essential in order to prevent these avoidable problems.

Keywords: F.Bs, ENT, Khartoum.

Corresponding Author: Sharfi Abdelgadir Omer Ahmed; email: doctorsharfi@gmail.com

Received: 15 June 2017
Accepted: 1 July 2017
Published: 4 July 2017

Production and Hosting by Knowledge E

© Dr. Rana Ahmed Abdelrahman Nasir et al. This article is distributed under the terms of the [Creative Commons Attribution License](#), which permits unrestricted use and redistribution provided that the original author and source are credited.

Editor-in-Chief:
Prof. Mohammad A. M. Ibnouf

 OPEN ACCESS

1. Literature Review

Foreign bodies (F.Bs) lodged within the ear, nose, larynx, trachea, pharynx and esophagus may present as a minor irritation or a life-threatening problem [1].

Multiple F.Bs are not uncommon, especially in small children, so all other orifices of the head should be inspected after removal of a foreign body from the external auditory canal [10].

Balbani AP, et al report that F.Bs are inserted into the ears more commonly by school children than by toddlers. In a review of 191 aural foreign bodies, 74 percent were in children aged from 6 to 12 years, small toys being the most common objects [6, 7].

Nasal F.Bs tend to be located on the floor of the nasal passage, just below the inferior turbinate, or in the upper nasal fossa anterior to the middle turbinate [13].

All pharyngeal F.Bs are medical emergencies that require airway protection, because complete airway obstruction may occur at the time of aspiration and results in immediate respiratory distress and so emergency intervention is essential. Common obstructing F.Bs in children include balloons, pieces of soft deformable plastic, and food boluses [15].

The most common F.Bs in the throat are pieces of plastic, metal pins, seeds, nuts, bones, coins, and dental appliances [1, 2].

Radiography can be helpful in localizing coins, button batteries, and other radiopaque objects, but most pharyngeal F.Bs, including fish bones, are radiolucent [12, 14].

Foreign Body aspiration by children in Sudan is not uncommon; especially those below the age of 5 years. Children are at risk because of their curious nature, strong oral tendency and lack of molar teeth. It usually affects the larynx and trachea and rarely the lungs [8, 16].

Sharfi AO reported that a total of 150 bronchoscopies were performed: 89 cases (56%) were below 2 years of age; 45 cases (30%) were between 2-5 years; and 18 cases (14%) were over 5 years of age. In 88 cases (58.7%) the foreign bodies inhaled were peanuts and in 27 cases (18%) were watermelon seeds, and most of the foreign bodies were found in children under five years of age. Pins and needles were found in 8 cases (5.3%) mostly in teenage females and most of the FBs (82.7%) were radiolucent showing minimal or no X-ray findings [18].

Yagi H reported that in Sudanese patients, most common FBs in the bronchi are peanuts (*Arachis hypogea*), and roasted watermelon seeds (*Citrullus vulgaris*) and there are three clinical phases with children presenting with foreign body inhalation, which consist of choking, gagging and paroxysms of coughing or airway obstruction. Plain X-rays of the chest were not helpful in the diagnosis, except in few cases (9.5%) where

the FBs were radio-opaque. Foreign body bronchus is usually removed successfully by rigid bronchoscopy [3].

2. Patients and Methods

It is a prospective hospital based descriptive study, conducted at Khartoum ENT, IbnSina and Africa Hospital in Sudan from March 2013 to January 2015.

3. Inclusion Criteria

Both males and females and patients of age groups below 16 years.

4. Data Collection

Data collection was achieved through well-designed questionnaire covering demographic clinical information.

5. Data Analysis

Data analysis was by using SPSS program. Data presentations were through tables, figures, percentages and cross tabulation ($P.V \geq 0.05$).

6. Ethical Considerations

Ethical clearance was taken from the hospital administrations and then I explained verbally to any patient the aim of the study, data collection, the need of investigations and regular follow up. Privacy of patient is the most of our priority

7. Results

A total of 150 patients with F.Bs were studied in Khartoum ENT Hospitals. Twenty-seven patients (18%) were below 2 years of age, 96 patients 64% were between 3-6years, and 27 cases (18%) were above 6 years of age table (1).

Concerning the gender of patients 86 of them (57.3%) were male and 64 patients (42.7%) were female, and male to female ratio was 1.3:1 fig (1).

Ninety-six patients (64%) were from urban areas, while 54 patients (36%) came from rural areas fig (2).

One hundred and six (70.7%) were of low socioeconomic status, while 44 patients (29.3%) were of moderate socioeconomic status fig (3).

Seventy-two patients (48%) were brought for help within 24 hours, while 42 (27.9%) after 24 hours to 1 week, 31 (20.6%) after 1 week to 1 month and 5 (3.5%) were seen more than one month. Thirty-seven cases (24.7%) were presented F.Bs inhalations, 34 cases (22.7%) were presented with foreign bodies ingestion, 42 cases (28%) were presented with the F.Bs nose and 37 cases (24.7%) were presented with the F.Bs ear fig (4).

In 37 cases (24.7%) patients presented with foreign bodies inhalations, 21 patients (56.8%) inhaled peanut, four cases (10.8%) inhaled water- melon seeds, 4 cases (10.4) inhaled plastic material and 2 cases (5.4%) inhaled metallic material. Vegetables were inhaled in 4 cases (10.8%) and Adasia (Type of seeds planted in Gezira State) in 2 cases (8.1%) table (2).

Patients with foreign bodies inhalations presented with different symptoms, 35 of them (94.5%) complain of cough. Shortness of breath is presented in 26 patients (70.2%), fever is presented in 23 (62.1%), increased respiratory rate in 22 of patients (59.5%), Chest in drawing in 13 patients (35.1%), wheezy chest in 24 patients (64.9%), decrease air entering in 20 patients (54.1) and Crepitation in 17 patients (45.9%) table (3).

In 34 cases (22.7%) patients presented with foreign bodies ingestion: 23 patients (67.6%) ingested Coin, 4 cases (11.8%) ingested other metallic material, two cases (5.9%) ingested fish bone, two cases (5.9%) ingested vegetables and one case (2.9%) ingested bone table (4).

These patients (34) presented with different symptoms, 32 patients (94.1%) complain of dysphagia. Drooling of saliva was presented in 31 case (91.2%), vomiting in 21 cases (61.8%), odynophagia in 3 cases (8.8%) and 2 patients (5.9%) complained of difficulty in breathing. Only one patient (2.9%) presented with choking table (5).

In 37 cases, patients inserted foreign bodies in the ear: 14 cases (37.8%) inserted Adasia, 11 cases (29.8%) inserted vegetables, 8 cases (21.6%) inserted Plastic material and 4 patients (10.8%) inserted metallic material table (6).

Regarding clinical presentation, 31 of patients (83.8%) brought to medical attention by their parents and complained that, their children inserted foreign bodies in their ears. Five of them (13.5%) presented with aural pain and heaviness in three patients (8.0%). Hearing impairment and Otorrhoea were present in four patients (10.8%) table (7).

F.B nose was found in 42 cases (28%); 27 of them (64.3%) inserted vegetables, 11 patients (26.2%) inserted plastic material and 4 patients (9.5%) inserted metallic material table (8).

Age	Number of patients	percentage
0- 2yrs	27	18.0%
3- 4yrs	73	48.7%
5- 6yrs	23	15.3%
7- 8yrs	17	11.3%
9- 10yrs	5	3.3%
11- 12yrs	3	2%
13- 14yrs	2	1.3%
Total	150	100%

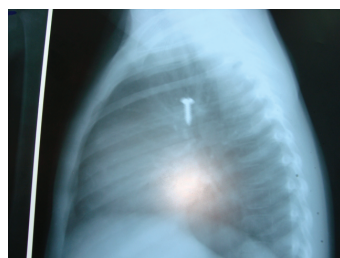
TABLE 1: Age distribution among the patients.

Type of FB	Frequency	Percentage
Peanut	21	56.8%
Watermelon	4	10.8%
Plastic material	4	10.8%
Metallic material	2	5.4%
Vegetables	4	10.8%
Adasia	2	5.4%
Total	37	100%

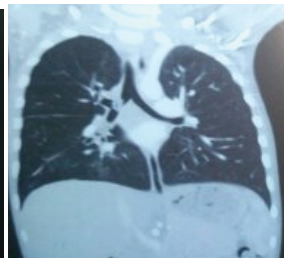TABLE 2: Type of FBs Inhalation among the patients (No. of patient 37).

Nasal obstruction was a symptom in 36 of cases (85.7%) and 33 patients (78.6%) presented with nasal discharge. Unilateral offensive nasal discharge and itching were presented in 9 patients (21.4%). Two patients (4.8%) presented with Epistaxis table (9).

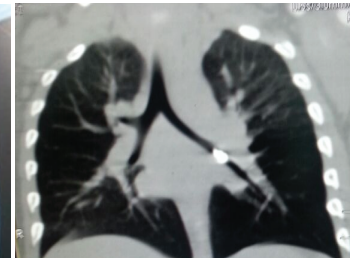F.B bronchus screw



F.B Rt bronchus peanut



F.B Lt bronchus Metallic material



8. Discussion

Despite several reports in the literature and emphasis on the dangers of foreign bodies in ENT, it remains a persistent problem in Sudan. Children constituted near one third of

Clinical Presentation	Frequency	Percentage
Shortness of Breath	26	70.2%
Cough	35	94.5%
Hoarseness of Voice	3	8.1%
Choking	4	10.8%
Stridor	8	21.6%
Increased RR	22	59.5%
Chest in drawing	13	35.1%
Subcostal recession	10	27.0%
Decrease air entering	20	54.1%
Crepitation	17	45.9%
Wheeze	24	64.9%
Fever	23	62.1%
Grunting	3	8.1%
Cyanosis	2	5.4%

TABLE 3: Clinical Presentation of FB Inhalation (No. of patient 37).

Type of FB	Frequency	Percentage
Coin	23	67.6%
Metallic material	4	11.8%
Plastic material	2	5.9%
Fish bone	2	5.9%
Bone fragment	1	2.9%
vegetables	2	5.9%
Total	34	100%

TABLE 4: Type of FBs Ingestion among the patients (No. of patient 34).

Clinical Presentation	Frequency	Percentage
Dysphagia	32	94.1%
Odynophagia	3	8.8%
Vomiting	21	61.8%
Drizzling of saliva	31	91.2%
Shortness of Breath	2	5.9%
Choking	1	2.9%

TABLE 5: Clinical Presentation of FB Ingestion (No. of patients 34).

Type of FB	Frequency	Percentage
Adasia	14	37.8%
Plastic material	8	21.6%
Metallic material	4	10.8%
vegetables	11	29.8%
Total	37	100%

TABLE 6: Type of FB ear (No. of patient 37).

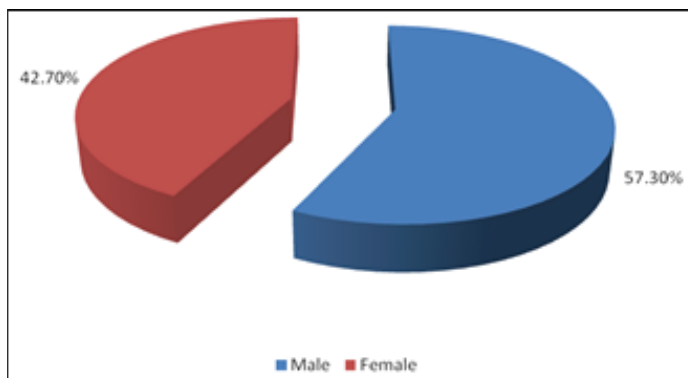


Figure 1: Gender distribution among the patients.

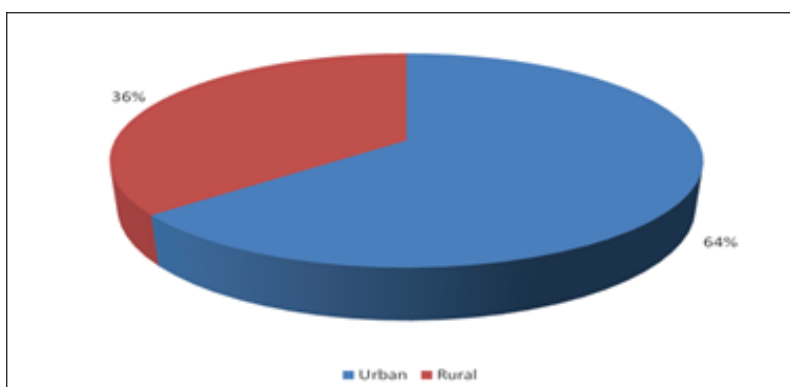


Figure 2: Residence distribution among the patients.

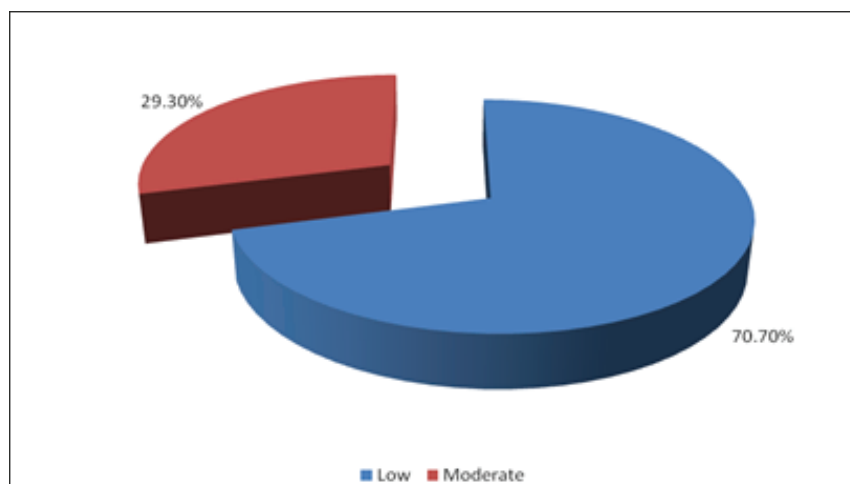


Figure 3: Socio-economic status of the patients.

all admissions and almost two third of the surgical emergencies in the ENT hospitals. This reflects a significant large work load exerted by this important age group [4, 19].

Most cases (82%) occurred below 6 years; with a male to female ratio 1.3:1.0, this agree with Osman W.N. and Elmustafa [6, 19]. The sites of impaction were; bronchus (24.7 %), pharyngoesophageal (22.7%), ear (24.7%) and nose (28%). The authors

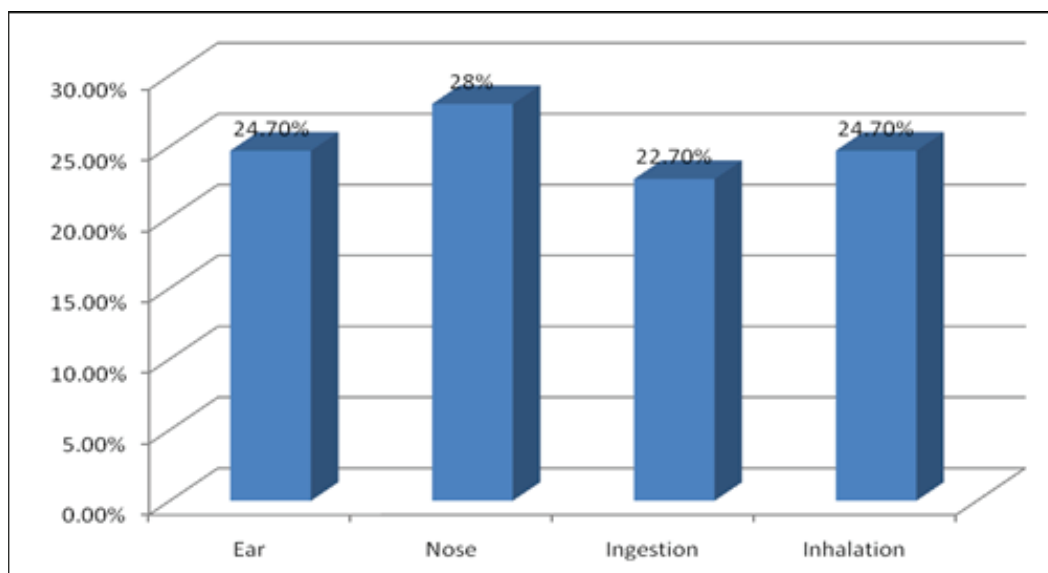


Figure 4: Site of FB among all patients.

Clinical Presentation	Frequency	Percentage
Insertion of FB by them self	31	83.8%
Aural pain	5	13.5%
Otorrhoea	4	10.8%
Hearing impairment	4	10.8%
Heaviness	3	8.0%

TABLE 7: Clinical Presentation of FB ear (No. of patient 37).

explain that their percentages in the cases of F.Bs ear and the nose were higher than those reported by Osman W.N. and Elmustafa [11, 19].

Apart of the children neglected and disturbed the house environment are predisposing factor for foreign bodies impaction, this agree with Osman W.N. and Elmustafa [6, 19].

Foreign bodies aspiration is a life- threatening condition. In this study, it was found that less than 2years (45.9%) are the most affected group and this agree with El-Mustafa O.M. and Sharfi A.O [4, 8, 18].

Type of FB	Frequency	Percentage
plastic material	11	26.2%
metallic material	4	9.5%
vegetables	27	64.3%
Total	42	100%

TABLE 8: Type of FB nose (No. of patients 42).

Clinical presentation	Frequency	Percentage%
Nasal obstruction	36	85.7%
Unilateral offensive nasal Discharge	9	21.4%
Itching	9	21.4%
Epistaxis	2	4.8%
Insertion of FB	33	78.6%
Nasal discharge	35	83.3%

TABLE 9: Clinical Presentation of FB Nose (No. of patient 42).

Foreign bodies aspiration was the most common indication for surgical intervention in children below five years. This has been attributed to anatomical factors such as poor chewing ability, wide and high larynx compare with adult, physiological factors such as poor refluxes and protective mechanism, developmental factors as this the age of exploration of things, this agree with Osman W.N. and Elmustafa [11, 19].

In our study (64.9%) were from rural areas, while 54 patients (35.1%) came from urban areas. This was naturally expected, as the peanuts which are common FBs in our series (56.8%), were planted. Mainly in rural areas and the community is not aware of the hazards of peanuts, and this agree with Sharfi A.O [18].

Peanuts were found in children below the age of 5 years, while plastic and metallic foreign bodies were encountered in older children and teenagers, and this agrees with Sharfi A.O [18].

Cough is the commonest presenting symptom (94%) followed by shortness of breath (70.2%) and wheeze in (64.9%) and this in agreement with El-Mustafa O.M, Osman W.N et al, Sharfi A.O and Memon [8, 17–19].

Organic foreign bodies are liable to cause laryngotracheobronchitis and predispose to lung infection. Therefore, inhaled FB should be suspected in children with history of repeated chest infection not responding to antibiotics, this is also reported by Sharfi A.O [4, 18].

Foreignbody esophagus was a common problem in the Sudanese children. There was 73.5% male preponderance and it was clear that the commonest type of foreign bodies was coins (67.9%), and this agrees with Silsua A [20].

Dysphagia was the commonest presenting symptom (94.1%), and patients presented immediately to the out-patient complaining of discomfort, especially when the foreign body was impacted in the hypopharynx or the cervical esophagus, this in agreement with Silsua A [20].

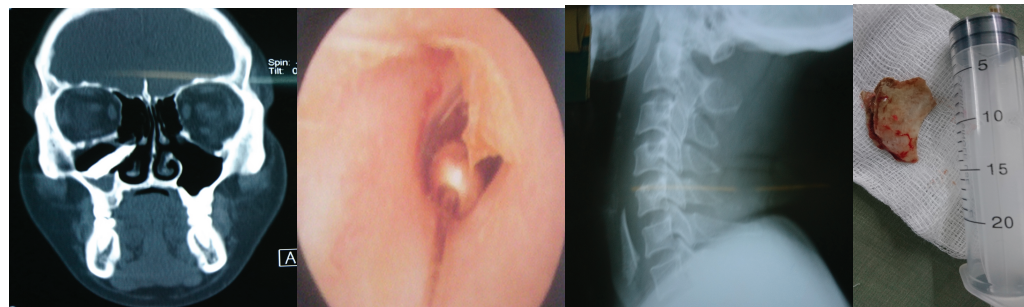
Foreign body nose was a common problem in children between (3-4) years and the commonest gender (64.2%) was female. The commonest type of foreign bodies were vegetables, and this is similar to Kadish H.A [5].

Nasal obstruction is a major presenting symptom in the first three days (85.7%), after that children presented with unilateral offensive discharge (21.9%), and this was similar to Kalan A [9].

Foreign body ear was common in children more than six years and (59.4%) were female, which was the commonest gender, this in agreement with Balbani A.P [7].

The commonest type of foreign bodies in the ear of Sudanese children were Adasia (37.8%) which is different from Balbani A.P, et al who report that, small toys being the most common objects in (43%) [7].

As for the ear this perhaps the only site that early patients were asymptomatic, but reported with a positive history of insertion of foreign body (56.8%) by one self or by another. Patient may present with multiple foreign bodies, this agree with Thompson S.K. et al [10].



F.B bullet Rt nose

F.B on the Ear

F.B bone in the hypopharynx

9. Conclusion

F.Bs in ear, nose and throat are a common problem in Sudanese children. In this study the authors found , the nose was the commonest site for FBs, while the second sites were the ear and inhaled foreign bodies but the ingested foreign bodies were the least. It is noted that there was no highly gross difference in the percentages. The commonest inhaled foreign body (56.8%) were peanuts. As for the ear, nose and ingested foreign bodies ,Adasia, plastic materials and coins were the most encountered foreign bodies respectively. As for the commonest presenting symptoms cough in inhaled F.Bs,dysphagia in ingested ,obstruction in the nose. Most patients (82%) were below the age of 6 years and most (70.7%) were of low socioeconomic status.

10. Abbreviations

FBs	Foreign bodies
ENT	Ear nose throat
Adasia	Type of seeds planted in Gezira State

References

- [1] R. M. Esclamado and M. A. Richardson, "Laryngotracheal Foreign Bodies in Children: A Comparison With Bronchial Foreign Bodies," *American Journal of Diseases of Children*, vol. 141, no. 3, pp. 259-262, 1987.
- [2] V. Gautam, J. Phillips, H. Bowmer, and M. Reichl, "Foreign body in the throat.," *Emergency Medicine Journal*, vol. 11, no. 2, pp. 113-115, 1994.
- [3] H. Yagi, "Foreign Body in the tracheobronchial tree in Sudanese patients," *J-R-Coll-Surg-Edib*, vol. 42, no. 4, pp. 235-237, 1997.
- [4] F. A. Fadl and M. I. A. Omer, "Tracheobronchial foreign bodies: A review of children admitted for bronchoscopy at King Fahd Specialist Hospital, Al Gassim, Saudi Arabia," *Annals of Tropical Paediatrics*, vol. 17, no. 4, pp. 309-313, 1997.
- [5] H. A. Kadish and H. M. Corneli, "Removal of nasal foreign bodies in the pediatric population," *American Journal of Emergency Medicine*, vol. 15, no. 1, pp. 54-56, 1997.
- [6] J. F. Ansley and M. J. Cunningham, "Treatment of aural foreign bodies in children," *Pediatrics*, vol. 101, no. 4, pp. 638-641, 1998.
- [7] A. P. S. Balbani, T. G. Sanchez, O. Butugan et al., "Ear and nose foreign body removal in children," *International Journal of Pediatric Otorhinolaryngology*, vol. 46, no. 1-2, pp. 37-42, 1998.
- [8] O. M. Elmustafa, Bronchial F.B in Sudanese children. Arab Board of medical specializations J. 199; 4: 21-3.
- [9] A. Kalan and M. Tariq, "Foreign bodies in the nasal cavities: A comprehensive review of the aetiology, diagnostic pointers, and therapeutic measures," *Postgraduate Medical Journal*, vol. 76, no. 898, pp. 484-487, 2000.
- [10] S. K. Thompson, R. O. Wein, and P. O. Dutcher, "External Auditory Canal Foreign Body Removal: Management Practices and Outcomes," *Laryngoscope*, vol. 113, no. 11, pp. 1912-1915, 2003.
- [11] P. J. Robinson, "Laryngeal foreign bodies in children: First stop before the right main bronchus," *Journal of Paediatrics and Child Health*, vol. 39, no. 6, pp. 477-479, 2003.
- [12] M. Kumar, G. Joseph, S. Kumar, and M. Clayton, "Fish bone as a foreign body," *Journal of Laryngology and Otology*, vol. 117, no. 7, pp. 568-569, 2003.
- [13] T. C. Chan, J. Ufberg, R. A. Harrigan, and G. M. Vilke, "Nasal foreign body removal," *Journal of Emergency Medicine*, vol. 26, no. 4, pp. 441-445, 2004.
- [14] A. Ngo, K. C. Ng, and T. P. Sim, "Otorhinolaryngeal foreign bodies in children presenting to the emergency department," *Singapore Medical Journal*, vol. 46, no. 4, pp. 172-178, 2005.
- [15] D. C. Bloom, T. E. Christenson, S. C. Manning et al., "Plastic laryngeal foreign bodies in children: A diagnostic challenge," *International Journal of Pediatric Otorhinolaryngology*, vol. 69, no. 5, pp. 657-662, 2005.

- [16] T. Hilliard, "Delayed diagnosis of foreign body aspiration in children," *Emergency Medicine Journal*, vol. 20, no. 1, pp. 100–101.
- [17] F. Orji and J. Akpeh, "Tracheobronchial foreign body aspiration in children: how reliable are clinical and radiological signs in the diagnosis?" *Clinical Otolaryngology*, vol. 35, no. 6, pp. 479–485, 2010.
- [18] A. O. Sharfi, "Prevalence, management and complications of foreign body bronchus in Sudanese children," *Sudan JMS*, vol. 7, pp. 45–48, 2012.
- [19] W. N. Osman and O. M. El-Mustafa, "Common ORL Surgical Emergencies in Sudanese Children," *Sudan JMS*, vol. 7, pp. 175–178, 2012.
- [20] A. Pinto and L. Romano, *Imaging of Foreign Bodies*, Springer Milan, Milano, 2014.