

## Case Report

# Recurrent Solitary Clavicular Parosteal Osteoma 25 Years after Surgical Resection

Mesut Mısırlıoğlu

Department of Orthopedics And Traumatology, Dr Abdurrahman Yurtaslan Ankara Oncology Training and Research Hospital, Yenimahalle/Ankara, Türkiye

### Abstract

Osteoma is a slowly growing, asymptomatic, benign osteogenic tumor. An extremely rare case of clavicular parosteal osteoma (PO) is reported. A 46-year-old female patient was treated with marginal resection after an open biopsy for a large, firm symptomatic mass originating from the middle part of the left clavicle, which recurred 25 years after surgery. In the fifth year postoperatively, the patient was followed up with a full range of motion of the left shoulder without any problem in her daily life. In this case report, the clinical course, imaging findings, diagnosis, and long-term results of a rare case of parosteal osteoma recurrence of the clavicle are described for the first time in the literature.

**Keywords:** clavícula, osteoma, recurrence, marginal resection, benign bone tumor

Corresponding Author: Mesut Mısırlıoğlu; email: mesutmisirlioglu44@gmail.com

Received 12 June 2022

Accepted 31 January 2023

Published 31 March 2023

Production and Hosting by  
Knowledge E

© Mesut Mısırlıoğlu. This article is distributed under the terms of the [Creative Commons Attribution License](#), which permits unrestricted use and redistribution provided that the original author and source are credited.

Editor-in-Chief:

Prof. Nazik Elmalaika Obaid  
Seid Ahmed Husain, MD,  
M.Sc, MHPE, PhD.

## 1. Introduction

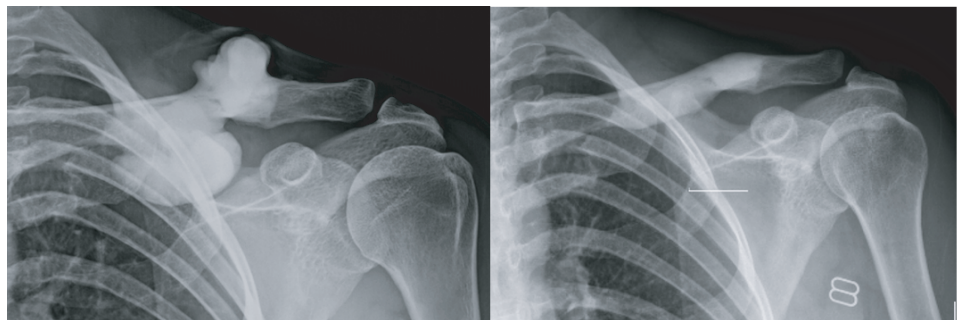
Osteomas are usually asymptomatic, slowly growing solitary benign osteogenic tumors derived from the bone surface. It is mostly seen in the skull and facial bones [1]. Extracranial solitary osteomas are rare, and the clavicle is an extremely rare location for parosteal osteoma (PO) [2–4]. The most common extracranial localization is in the lower extremities [5]. Clinically, they usually appear as circumscribed, rounded, and protruding masses [2]. Excision of the masses, which are usually asymptomatic and detected incidentally, is necessary for the presence of significant symptoms [5, 6]. Histologically, POs consist of dense sclerotic lamellar bone, similar to cortical bone [2]. In this study, we aimed to present the clinical course, management, and postoperative long-term outcomes of solitary clavicular PO recurrence.

## 2. Case Presentation

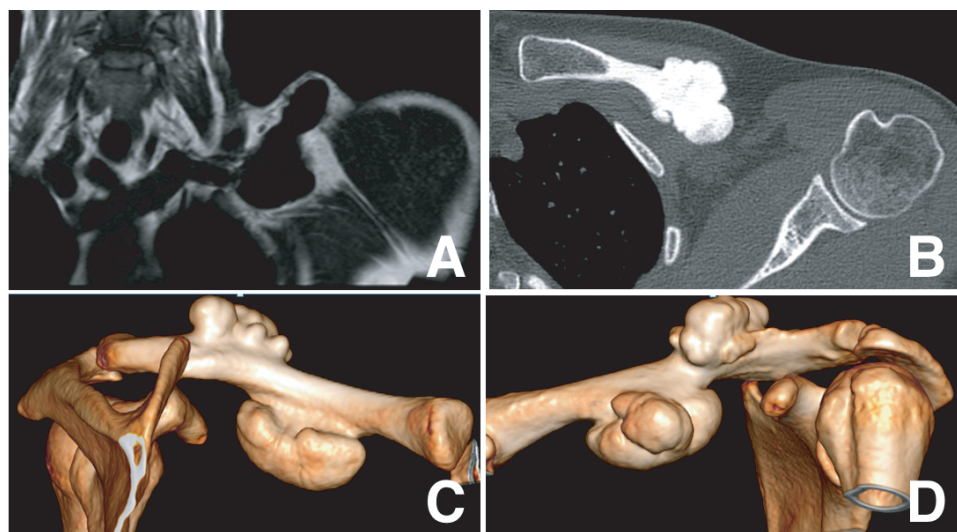
A 46-year-old female patient presented with a large palpable mass and pain in the left supraclavicular fossa. The histopathological result of the excisional biopsy performed 25

 OPEN ACCESS

years ago due to similar complaints was reported as compact bone tissue. The lesion, which was first noticed as a palpable mass five years ago, was followed up. She had a solid fixed, non-tender bony mass with bumpy lines. Physical examination revealed limitation of shoulder abduction and internal rotation, and tension on the palpable mass. Radiological examination revealed a solid sclerotic mass, 63×29 mm-sized, lobulated contoured, extending to the clavicular cortex (Figures 1, 2). A cortical thickening of the clavicular bone adjacent to the well-circumscribed mass was observed, which was attached to the clavicle with a wide border, but there was no invasion, bone destruction, or soft tissue involvement (Figure 2). The patient requested surgical removal of the mass due to pain, cosmetic reasons, shoulder limitation, and risk of pressure on sub-clavicular neurovascular structures.

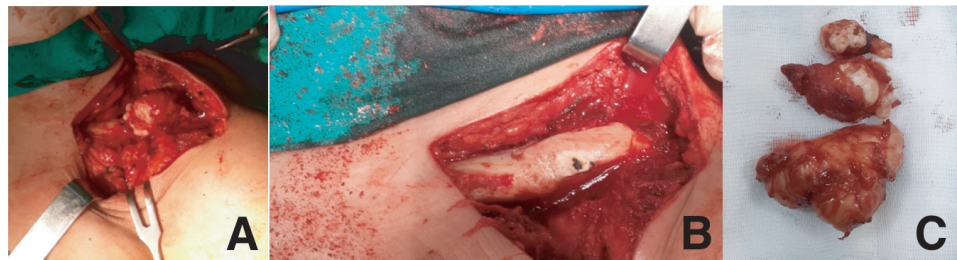


**Figure 1:** Left shoulder radiographs showing osteodense solid homogenous mass around the mid-clavicle in preoperative imaging (a) and postoperative imaging (b).

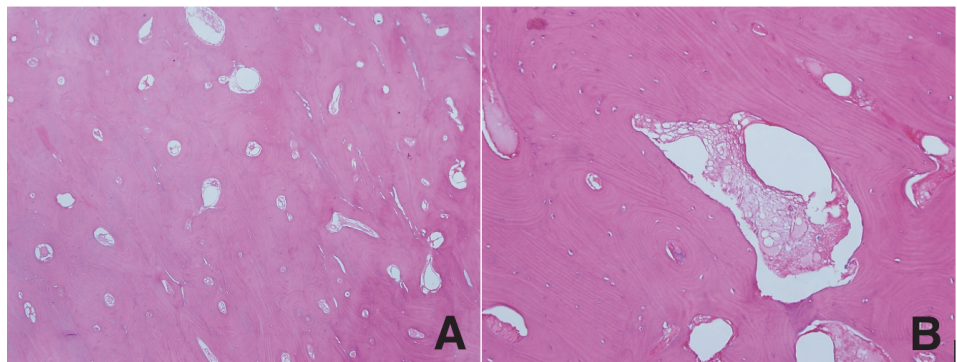


**Figure 2:** Radiological images of left clavicular parosteal osteoma (a) scintigraphic cold uptake imaging, (b) computerized tomography axial imaging, (c) 3-dimensional imaging from posterior aspect, and (d) 3-dimensional imaging from anterior aspect.

Open biopsy results were reported as bone trabeculae, hypertrophic callus, or osteoma for reasons such as deep localization, bipartite lobulization, >5 cm size,



**Figure 3:** (a) Intraoperative view of the antero-superior part of the left mid-clavicular parosteal osteoma. (b) Same view after marginal resection. (c) Bone fragments excised with reduction surgery.



**Figure 4:** Clavicular parosteal osteoma histopathological imaging (a) dense compact sclerotic bone with prominent haversian system (HE $\times$ 100). (b) Irregular haversian system is noticed due to focal resorptive activity (HE  $\times$ 400).

recurrence, and suspicion of malignancy. A marginal resection with the sagittal saw and osteotomes was performed to remove the bony mass. It could be removed by reduction surgery in the form of bony fragments, as the lesion was hard as marble and sclerotic (Figure 3). Microscopic examination of the histopathological diagnosis confirmed osteoma and showed dense, hypocellular, sclerotic concentric parallel lamellar bone trabeculae (Figure 4). Early shoulder movements were started in the first postoperative week, and the patient's complaints were completely resolved. The asymptomatic patient, who has no problems with the left clavicle in the fifth postoperative year, can easily perform her daily activities without any restrictions.

### 3. Discussion

Primary tumors originating from the surface of the clavicle, such as PO, are so rare that they constitute 3.8% of all clavicle primary tumors [4]. In a study of 40,000 patients with tumors, the Mayo Clinic identified 14 cases of PO, of which only one was clavicular PO [1]. Recurrence of PO is very rare [1, 5]. As in our case, the outcome of a clavicular PO recurrence who underwent surgical excision is presented for the first time in the literature.

POs are lesions that are usually asymptomatic, incidentally identified by X-ray, and <3 cm in size [6–8]. As they grow slowly over time, they can cause symptoms of pain, swelling, and compression [2, 9]. They are usually seen in the fourth or fifth decades and tend to grow slowly over a long period [1, 2]. Based on the literature, surgical resection of the symptomatic clavicular mass was performed first at the age of 21, recurred within 25 years, reaching 6 cm in size and causing pain, movement limitation, and compression symptoms.

The lesion typically appears as a well-circumscribed, radiopaque, and homogeneous bony mass with smooth borders on conventional radiographs which is the basic imaging technique used for diagnosis [2, 8]. It can be seen on CT and MRI scans that the osteoma is homogeneously combined with the ossified cortex and is sclerotic without intramedullary invasion or periosteal reaction [2, 5, 8]. The case we presented in this study was a lobulated mass with a homogeneous dense circumference and base, the same signal intensity as the cortex, without cartilage cover, and with clear cortical edges. Similarly, the case we presented in this study was a broad-based, homogeneous dense, circumference lobulated mass with clear cortical edges, without cartilage cover.

Appropriate biopsy selection, which should be performed when malignancy is suspected, is important for accurate diagnosis [4]. Conservative treatment is preferred in asymptomatic cases, rather than performing extensive and debilitating surgical procedures [2, 8]. If PO is symptomatic and causes atypical clinical and radiographic findings, surgical treatment is recommended. Since recurrence is rare and malignant transformation has not been reported, it is indicated that marginal resection is sufficient in cases diagnosed preoperatively [1, 2, 5]. We thought that it would be sufficient to remove recurrent, segmental atypical masses close to neurovascular structures by marginal resection after biopsy.

The differential diagnosis of PO includes radiopaque masses such as osteochondroma, osteoblastoma, fibro-osseous lesions, heterotrophic ossification, and parosteal osteosarcoma [2, 6, 8]. The definitive pathology report of a patient who underwent wide resection and pneumonectomy with the preliminary diagnosis of parosteal osteosarcoma after a biopsy from the clavicular mass was cortical bone tissue and osteoma [3]. Likewise, the final pathology of the patient, who underwent extensive clavicle resection and allograft reconstruction with the suspicion of parosteal osteosarcoma and soft tissue involvement, was evaluated as PO [4]. It is crucial to distinguish parosteal osteosarcoma from PO [3, 7]. The slow clinical course of the mass for 25 years and the result of the open biopsy of our patient were evaluated in favor of PO. A satisfactory improvement in clinical and functional outcomes was achieved after marginal resection.

## 4. Conclusion

This case is unique in the literature as a recurrence of clavicular PO requiring a second surgical resection after 25 years. Even if PO is suspected based on clinical course and imaging findings, a biopsy may be required in atypical locations and findings. The lesion should be removed carefully due to elaborated operation. It should be kept in mind that recurrence may occur after surgical treatment of parosteal osteoma the uncertainty of growth potential, and patients should be followed carefully.

## 5. Acknowledgements

None.

## 6. Ethical Considerations

The author declares that the procedures were followed according to the regulations established by the Clinical Research and Ethics Committee and to the Helsinki Declaration of the World Medical Association updated in 2013. Patient consent was obtained.

## Competing Interests

None.

## Availability of Data and Material

All relevant data of this study are available to any interested researchers upon reasonable request to the corresponding author.

## Funding

This research received no specific grant from any funding agency in the public, commercial, or not-for-profit sectors.

## References

- [1] Bertoni, F., Unni, K. K., Beabout, J. W., & Sim, F. H. (1995). Parosteal osteoma of bones other than of the skull and face. *Cancer*, *75*(10), 2466–2473.
- [2] Inokuchi, T., Hitora, T., Yamagami, Y., Nishimura, H., & Yamamoto, T. (2014). Parosteal osteoma of the clavicle. *Case Reports in Orthopedics*, *2014*, 824959.
- [3] Saglik, Y., Kendi, T. K., Yildiz, H. Y., Erakar, A., Güngör, A., & Ereku, S. (2003). Clavicular osteoma associated with bronchial osteomas. *Skeletal Radiology*, *33*(4), 234–236.
- [4] Shin, D., Kim, W., & Park, J (2021). Allograft reconstruction for large parosteal osteoma of the clavicle: A case report. *Clinics in Shoulder and Elbow*, *24*(4), 261–264.
- [5] Vitiello, R., Greco, T., Cianni, L., Careri, S., Oliva, M. S., Gessi, M., De Martino, I., Bocchi, M. B., Maccauro, G., & Perisano, C. (2020). Bifocal parosteal osteoma of femur: A case report and review of literature. *Orthopedic Reviews*, *12*(1), 8673.
- [6] Zhou, B. G., Liu, M. Y., Lv, L. C., & Xia, H. (2014). Bone marrow osteoma of the tibia: A case report. *Oncology Letters*, *8*(6), 2776–2778.
- [7] Gümüstas, S., Ağır, I., Tosun, H. B., & Inan, H. M. (2013). An osteoma located on the radial head: A case report. *Journal of Clinical and Analytical Medicine*, *4*(3), 269–271.
- [8] Hansford, B. G., Pytel, P., Moore, D. D., & Stacy, G. S. (2015). Osteoma of long bone: An expanding spectrum of imaging findings. *Skeletal Radiology*, *44*(5), 755–761.
- [9] O'Connell, J. X., Rosenthal, D. I., Mankin, H. J., & Rosenberg, A. E. (1993). Solitary osteoma of a long bone. A case report. *Journal of Bone and Joint Surgery*, *75*(12), 1830–1834.