

Research article

Management of Fibrous Epulis of Anterior Maxillary Teeth: A Case Report of a 1.5-Year-Old Lesion

Mentari Salma Nurbaiti¹ and Kwartarini Murdiastuti^{2*}¹Periodontic Specialist Program, Faculty of Dentistry, Gadjah Mada University, Yogyakarta, Indonesia²Department of Periodontology, Faculty of Dentistry, Gadjah Mada University, Yogyakarta, Indonesia**ORCID**Kwartarini Murdiastuti: <https://orcid.org/0000-0001-5128-0944>Mentari Salma Nurbaiti: <https://orcid.org/0000-0002-1423-2190>**Abstract.**

Background: Epulis is a gingival hyperplasia (tumor-like) that originates from periodontal connective tissue. It can be caused by many factors such as a chronic local irritation. Epulis that grows on the anterior maxilla area can be inconvenient because it disrupts the aesthetics and also the function of the teeth. Therefore, it has to be completely removed by surgery.

Objective: To correct the condition of epulis by excision and gingival contouring for aesthetic need.

Case Report: A 30-year-old female patient presented with a complaint of a mass on the gum of the anterior teeth on her upper jaw that made her unconfident to smile. The mass had been there for 1.5 years.

Conclusion: The condition of epulis can be corrected by excision procedure and by removing the cause of the epulis (sub-gingival calculus). The aesthetic result can be obtained by gingival contouring after the excision.

Keywords: epulis, fibrous epulis, gingival hyperplasia, excision, gingival contouring, gingival biopsy

Corresponding Author:

Kwartarini Murdiastuti; email:
kmurdiastuti@ugm.ac.id

Published: 25 April 2022

Publishing services provided by
Knowledge E

© authors. This article is distributed under the terms of the [Creative Commons Attribution License](#), which permits unrestricted use and redistribution provided that the original author and source are credited.

Selection and Peer-review under the responsibility of the NaSSIP 6 Conference Committee.

1. Introduction

Swelling on the gingiva is usually lead to epulis diagnosis. Epulis is a gingival hyperplasia (tumor-like lesion of the gingiva). Lesions are swelling that is appear as a response to a chronic or recurring tissue injury, that will stimulate excessive response from the tissue [1,2]. Epulis is categorized into three main type that usually found: granulomatous epulis, fibrous epulis, and giant cell epulis [3]. Histologically, epulis contain of bundles of collagen fibers covered with keratinized squamous cell epithelium. Inflammatory infiltrate and ulcerated area will be seen also if the lesion get trauma (from chewing or brushing) [4].

OPEN ACCESS

Interdental papilla is the site that fibrous epulis usually appears. This happens as a result from local irritation (calculus, plaque, caries, radices, or irregular margins of restorations) [4]. The other causes of fibrous epulis are hormonal changes, pregnancy, and drugs (such as phenytoin) [2]. The lesion can be pedunculate or sessile [5]. The treatment for this condition includes excision of the lesion and gingival contouring [2]. In this paper, we will present a case of fibrous epulis on maxillary gingiva that is quite big for fibrous epulis on interdental papilla caused by subgingival calculus.

2. Case Report

A 30-year-old female patient came to the Prof. Soedomo Dental Hospital, complained about a mass on her gum of anterior teeth that made her unconfident when smiling. The mass had been there for 1,5 years. The patient felt no pain at the mass, the mass kept growing to its current state for 1 year. The mass stopped growing in the past 6 months. The patient last scaling treatment was 6 years ago. Two years ago, patient went through exodontia for her left first molar in mandible, it was not pulled out completely and patient was in pain during the exodontia. Couple days after the exodontia there was an abscess on the exodontia site that still had remaining radices. The patient was prescribed with analgesics and antibiotics by her dentist. The patient did not have a habit of smoking or consuming alcohol, and denied having a history of systemic illness or allergies, but her mom had history of leukemia and already healed.

Extraoral examination, there were no abnormalities. In intraoral examination, there was supra and subgingival calculus in all regions. Enlarge gum on labial side left lateral incisor sized 14 x 10 x 2 mm, reddish, un-stippling, fibrotic, well-defined (Figure 1)

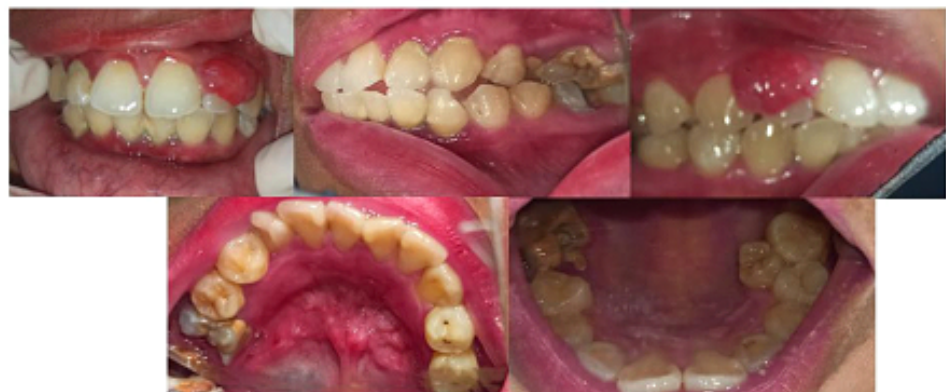

Figure 1: Intraoral photo shows intraoral condition on patients first visit. The gingival hyperplasia can be seen on the labial side of left lateral incisor with calculus sub and supra gingiva almost in all region of the mouth (Source: Author's documentation).

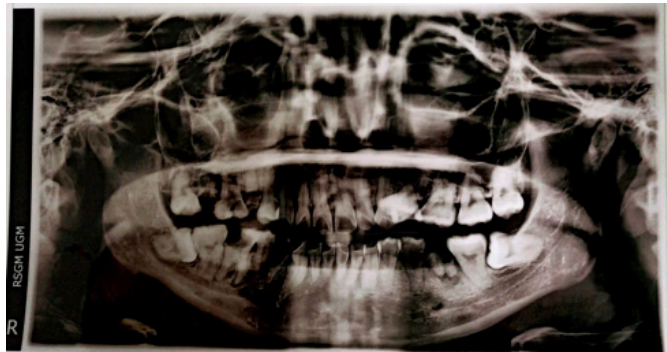


Figure 2: Panoramic radiograph taken on first visit, no bone loss around the left lateral incisor of the maxilla.

Based on all of the examinations on first visit it was concluded that the diagnosis of this case was gingival enlargement with the suspect of fibrous epulis, caused by local irritation from subgingival calculus. The prognosis was good considering patient motivation and age.

The treatment plans were initial phase therapy by scaling and root planning also dental health education to the patient. Patient were also given the prescriptions for taking panoramic radiography and also complete routine blood test. Blood test were taken because the history of the family and also the history of the previous dental treatment (Figure 3).

From the panoramic radiograph could be seen that there was no severe bone loss on the area of the left lateral incisor of maxilla. The blood test also shown normal, only some are higher and lower than the normal value due to the inflammation condition that was going on in patient's body.

On patient's second visit, excision of the epulis was performed. Before beginning the surgery, the patient was given explanations about the procedure. The patient agreed and signed the informed consent. Patient were healthy, already got the second dose of the covid19 vaccine and have normal vital sign. The procedure was done inside the negative chamber and the operator and the assistants were using level 3 personal protectiveequipment that was a necessity during this pandemic. Instruments and materials that would be used were prepared (diagnostic set, scalpel, blade no 15c, needle holder, scissors, nylon thread, gracey's curettes, orban knife, Kirkland knife, cytoject, local anaesthesia, povidone iodine, saline water, resopack)

Disinfection of the surgical area was done first using povidone iodine, before administering the local anaesthesia. The anaesthesia was done on the labial area of the surgical site (Figure 4). After that, nylon thread was used to hold the epulis so the margin can be seen as a guide for excision. Excision of the epulis was done using scalpel until the entire tissue of the epulis separated from the healthy gingiva, and excision done

until the stalk detach (Figure 5). The tissue then was put inside 10% of formalin and sent to the Pathology Anatomy Laboratory (Figure 9). As the epulis was removed, it was clearly shown that there was sub gingival calculus on the interdental of lateral incisor and canine. Root planning was done using gracey's curettes. After that, the gingival contouring was done using Kirkland and orban knives around the teeth until the crown was fully shown (Figure 6). Irrigation of the surgical site using saline water. Before putting on resopack, gingival of the surgical site was adapted so it could make a new attachment (Figure 7). Resopack was placed on the surgical area and covering all the excised gingival (Figure 8).

Dokter	: dr. Nining Krisyanti, SpPK		
Alamat	: Laboratorium Klinik Prodia JI. MT Haryono, Ruko Pandean		
No.Lab/Tgl.	: 2110060025 / 06-10-2021	Jenis Kelamin	: Perempuan
ID Pasien	: 0204210800082	Tgl.Lahir/Umur	: 19-02-1991 / 30 Tahun 7 Bulan
Nama Pasien	: Sdri. Rizky Febriyanti	Telepon	:
Alamat	: Dusun Kasihan RT 004, RW 007, Mudal : Temanggung		

Nama Pemeriksaan	Hasil	Nilai Rujukan	Satuan	Keterangan
HEMATOLOGI				
Hematologi Lengkap				
Hemoglobin	12.4	11.7 - 15.5	g/dL	Perempuan, Dewasa
Hematokrit	39.4	35 - 47	%	Perempuan, Dewasa
Eritrosit	4.65	3.8 - 5.2	10 ⁶ /μL	Perempuan, Dewasa
Nilai-nilai MC				
- MCV	84.7	80 - 100	fL	Dewasa
- MCH	26.7	26 - 34	pg	Dewasa
- MCHC	31.5	32 - 36	g/dL	5 tahun - Dewasa
RDW-CV	15.4	11.5 - 14.5	%	Dewasa
Trombosit	305	150 - 440	10 ³ /μL	Dewasa
Leukosit	7.1	3.6 - 11	10 ³ /μL	Perempuan, Dewasa
Hitung Jenis Leukosit				
- Basofil	0.0	0.0 - 1.0	%	
- Eosinofil	1.0	2.0 - 4.0	%	Dewasa
- Neutrofil	55.0	50.0 - 70.0	%	Dewasa
- Limfosit	43.0	25.0 - 40.0	%	Dewasa
- Monosit	1.0	2.0 - 8.0	%	Dewasa
LED	40	0 - 20	mm/jam	Perempuan, < 50 tahun

Pemeriksa,

Figure 3: Complete routine blood test result.

The patients were prescribed with 500mg amoxicillin every 8 hours for 5 days, 500 mg of mefenamic acid every 8 hours for 5 days, and chlorhexidine gluconate 0,2% twice daily for 4 weeks. After surgery instructions were given such as not to chew on the left side (surgical area), not to drink or eat anything hot for the first 24 hours, and take all the prescriptions on time. The patient was also instructed to comeback a week after surgery.

A week after surgery, the patient came back without any complain or discomfort. The gingiva on the surgery site was still erythematous, especially at the interdental

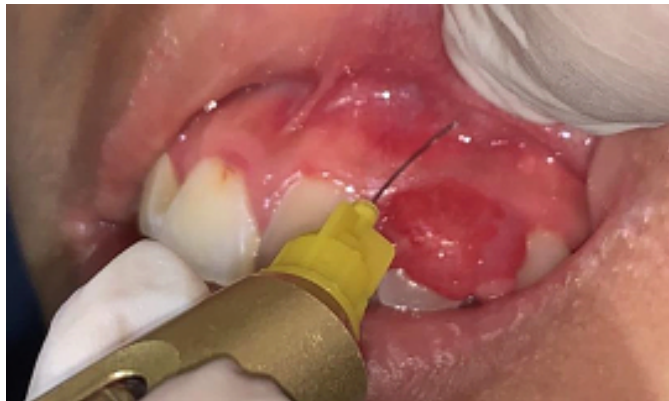

Figure 4: anaesthesia was done using infiltration method on labial gingival area. (Source: Author's documentation).

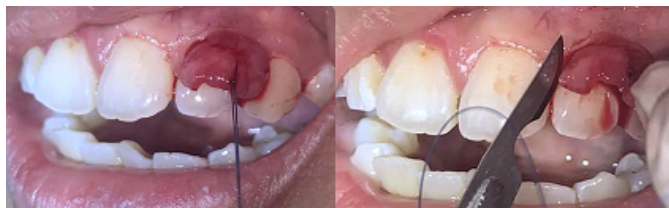

Figure 5: a nylon thread was used to hold the epulis, and excision was done using 15c blade. (Source: Author's documentation).

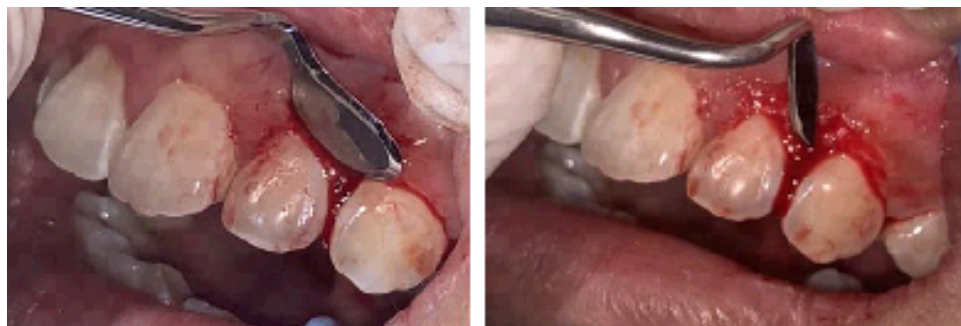


Figure 6: Gingival contouring using Kirkland and Orban knife (Source: Author's documentation).

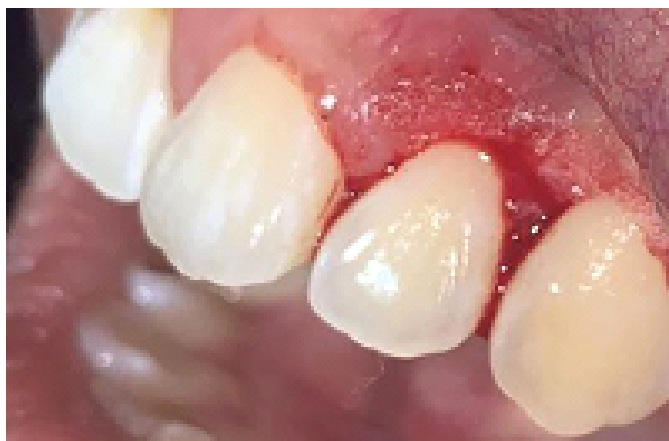

Figure 7: Gingiva after excision of epulis and gingival contouring (Source: Author's documentation).

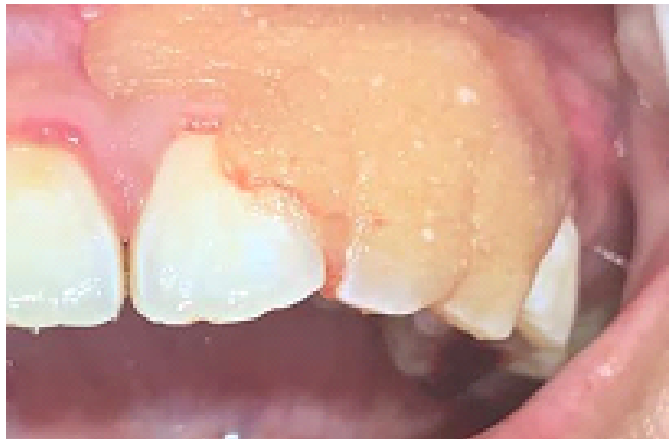

Figure 8: Resopack placement on surgery site (Source: Author's documentation).




Figure 9: Tissue sample that would be sent to be analysed on pathology anatomy department faculty of medicine Gadjah Mada University. (Source: Author's documentation).

of lateral incisor and canine (Figure 10). The pathology anatomy result was received and showed that the tissue was connective tissue covered with monomorphic complex stratified squamous epithelium, including ulceration on some areas. On sub epithelial area were fibrous connective tissues, and dominated with lymphocyte, ossification was also found. The conclusion from the analysis, the diagnosis was Fibrous Epulis (Figure 12).

On the second week after the surgery patient was recalled to see the healing progress of surgical site (Figure 11). The erythema was almost gone, only found on the tip of

interdental papilla of lateral incisor and canine. The patient was also satisfied with the result and gain more confidence.

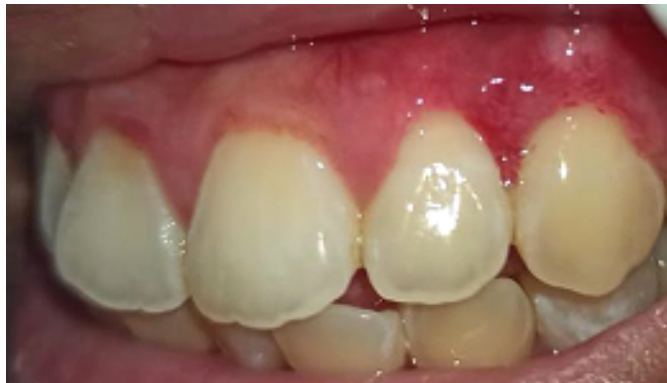

Figure 10: One week after the surgery. (Source: Author's documentation).

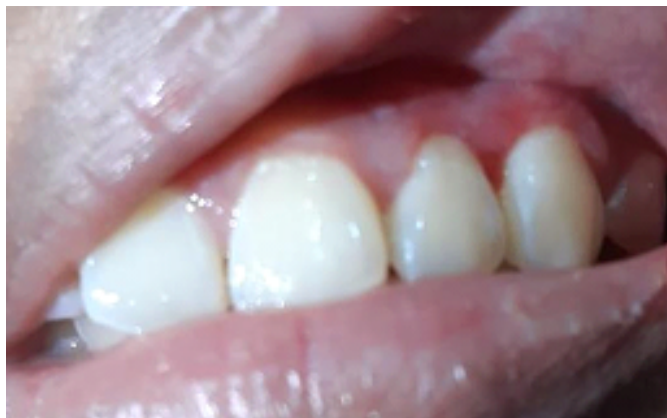

Figure 11: Two weeks after the surgery. (Source: Author's documentation).

3. Discussion

Swellings on the gingiva normally called epulis. Epulis is usually caused by gingival hyperplasia that happen due to trauma or systemic conditions. Fibrous epulis also come with the term fibrous inflammatory hyperplasia [6,7]. It is usually unpainful, but will caused some

trouble in chewing and also affect the aesthetic aspect if happened in the anterior region. It is slowly grown and will stop growing at a certain size [1,2]. Local aetiology for this patient is the subgingival calculus that were trapped on the interdental maxillary left lateral incisor and canine.

Previous studies found that fibrous lesion usually appear on patient aged 21 – 60 years old, and also the prevalence is higher in female compared to male. Another study

Organ : Gingiva bukal gigi 22
Makroskopis : 1 buah jaringan berukuran 1x0,7x0,5 cm, berwarna putih kecoklatan, kenyal, semua cetak.

Mikroskopis : Sediaan menunjukkan penonjolan jaringan ikat dilapisi epitel skuamous kompleks yang monomorf, sebagian kecil dengan ulserasi. Pada subepitel didapatkan jaringan ikat fibrous dengan sel-sel berinti spindle atau oval disebut sel radang berupa limfosit dominan, sel plasma dan leukosit PMN cukup. Didapatkan pula osifikasi. Tidak didapatkan tanda ganas.

Kesimpulan : Jaringan gingiva bukal gigi : Epulis fibromatosa.

Saran/NB: 1
 Pemeriksa :
 dr. Lili, dr. Nungki Anggerowati, Sp.PA(K), Ph.D

ICD-0T :
 ICD-OM:

Figure 12: The results of Pathology Anatomy analysis.

showed that gingival hyperplasia affects adult patients on their 3rd or 4th decade of life. It is relatable to our presented case that happened to a 30 years old female [8].

Fibrous epulis has some common clinical aspects such as well-defined encircle tissue on a smooth surface, usually same coloured with the surrounding tissue, sessile or pedunculated base, most of the time located on anterior maxilla in interdental papilla. In this case, the clinical appearance is the same with the description above [5,9]. But to make the definitive diagnosis is challenging for clinician. Thus, clinician normally check the histopathology of the tissue [10]. The result of the histopathology analysis is connective tissue covered with monomorphic complex stratified squamous epithelium, including ulceration on some areas. On sub epithelial area were fibrous connective tissues, and dominated with lymphocyte, ossification was also found, no malignancy indicated. The conclusion from the analysis, the diagnosis was Fibrous Epulis. According to the 10 th International Classification of Disease published by the WHO, fibrous epulis is classifies as ‘other disorder of the gingival and edentulous ridge’ (K06.8) [11].

The treatment for this case usually includes complete excision of the lesion and curettage of the surrounding area because most of the time it is originated from

periosteum and periodontal ligament. So, the curettage must be done thoroughly to prevent recurrency of the lesion. The commonly used instrument is surgical scalpel. But in some cases that suspected involving important vascular component, electrical scalpel or CO₂ laser are the choice, as they

can afford bloodless surgical site [12]. In this case we used surgical scalpel to make a controlled excision of the lesion. We are assured that the used of controlled excision, curettage and root planning on the periodontal membrane and periosteum will eliminate the irritants and can avoid recurrency. A gingivectomy also performed to recontouring the gingival margin of the teeth so we can get the aesthetic goal of the surgery.

4. Conclusion

Fibrous epulis is a tumor-like lesion that it unpainful and benign. It can grow to a certain size and stop growing. In this case fibrous epulis was originated from the subgingival calculus hidden in interdental maxillary left lateral incisor and canine. The treatment of excision and gingival contouring was performed by surgical scalpel. Curettage and root planning was done thoroughly to eliminate all the stalk and prevent recurrence of the lesion. Patient was satisfied with the result.

5. Acknowledgements

The authors would like to thank the staffs and supervisors of Department of Periodontology, Gadjah Mada University for the assistance. There is no conflict of interest stated by the author regarding this case.

References

- [1] Scully C. Oral and maxillofacial medicine: The basis of diagnosis and treatment. 2nd ed. Edinburg: Churchill Livingstone; 2008.
- [2] Dabholkar JP, Vora KR, Sikdar A. Giant fibrous epulis. Indian Journal of Otolaryngology and Head & Neck Surgery. 2008;60(1):69-71. <https://doi.org/10.1007/s12070-008-0022-0>
- [3] Liu C, Qin ZP, Fan ZN et al. New treatment strategy for granulomatous epulis: Intralesional injection of propranolol. Medical Hypotheses. 2012;78(2):327– 329.
- [4] Kfir Y, Buchner A, Hansen LS. Reactive lesions of the gingiva. A clinicopathological study of 741 cases. Journal of Periodontology. 1980;51(11):655–661.

- [5] Alam MN, Chandrasekaran SC, Valiathan M. Fibroma of the gingiva: A case report of a 20 year old lesion. *International Journal of Contemporary Dentistry*. 2010;1(3):107–109.
- [6] Bataineh A, Al-Dwairi ZN. A survey of localized lesions of oral tissues: A clinicopathological study. *The Journal of Contemporary Dental Practice*. 2005;6(3):30-39.
- [7] Reddy S. *Essentials of clinical periodontology and periodontics*. 3rd ed. Bengaluru: Jaypee; 2011.
- [8] Peralles PG, Viana APB, Azedevo ALR, Pires FR. Gingival and alveolar hyperplastic reactive lesions: Clinicopathological study of 90 cases. *Brazilian Journal of Oral Science*. 2006;5(18):1085-1089.
- [9] Ajagbe HA, Daramola JO. Fibrous epulis: Experience in clinical presentation and treatment of 39 cases. *Journal of the National Medical Association*. 1978;70(5):317–319.
- [10] Rajanikanth BR, Srinivas M, Suragimath G et al. Localized gingival enlargement — A diagnostic dilemma. *Indian Journal of Dentistry*. 2012;3(1):44–48.
- [11] Canadian Institute for Health Information. *International statistical classification of diseases and related health problems, Vol. 1 – Tabular list*. 10th ed. Ottawa: Canadian Institute for Health Information; 2012.
- [12] Tamarit-Borra M, Delgado-Molina E, Berini-Ayte L et al. Removal of hyperplastic lesions of the oral cavity. A retrospective study of 128 cases. *Medicina Oral, Patologia Oral y Cirugia Bucal*. 2005;10(2):151–162.