



## Research article

# Prosthetic Rehabilitation With Immediate Denture for Periodontally Hopeless Teeth: A Case Report

Zuelkevin<sup>1\*</sup>, Endang Wahyuningtyas<sup>2</sup>, Heriyanti Amalia Kusuma<sup>2</sup><sup>1</sup>Prosthodontics Resident, Gadjah Mada University, Yogyakarta, Indonesia<sup>2</sup>Department of Prosthodontics, Gadjah Mada University, Yogyakarta, Indonesia**ORCID:**Zuelkevin: <https://orcid.org/0000-0003-3585-5618>**Abstract.**

**Background:** Patient with poor oral hygiene may have periodontally diseased teeth with hopeless prognosis. The treatment is usually teeth extraction, which may be unpleasant to the patient because it can affect their appearance, speech and stomatognathic systems. It can be prevented by prosthetic rehabilitations with immediate denture. Immediate denture is a prosthodontic appliance to replace teeth and its subsequent structures which is inserted after tooth extractions.

**Objectives:** To observe immediate denture as a prosthetic rehabilitation treatment to replace periodontally hopeless teeth.

**Case Report:** We report a case of a 48-year-old woman with poor oral hygiene and elongated and mobile teeth which affected her chewing, speaking and appearance. The patient denied edentulous period. Patient management included subjective and objective examinations, preprosthetic treatment, impressions taking, diagnostic cast and working cast fabrications. Since try-in was impossible, midline position, tooth size and shade were taken in the early visit. Maxillomandibular relationship was determined and transferred to articulators. Cast modification with spatial modeling method, tooth set-up, wax modelling and insertion was done. Immediate denture was inserted right after the teeth extraction. Post-insertion control was done after one day, one week and one month.

**Results:** The results were esthetically satisfactory with acceptable occlusion, speech, retention and stabilization.

**Conclusion:** Immediate denture can be considered as a predictable treatment to replace hopeless teeth, which will restore esthetics, occlusions and speech with satisfactory retention and stabilization.

**Keywords:** immediate denture, periodontally hopeless teeth, prosthetic rehabilitation

## 1. Introduction

Periodontitis is a multifactorial disease and is strongly affected by oral hygiene. Severe periodontitis with the presence of worsening factors such as inadequate bone support and poor oral hygiene usually has a hopeless prognosis and extraction is usually indicated [1–3]. Tooth extractions will cause several problems, such as affecting the

Corresponding Author:

Zuelkevin; email:

zuelkevin@gmail.com

Published: 25 April 2022

Publishing services provided by  
Knowledge E

© Zuelkevin. This article is distributed under the terms of the [Creative Commons Attribution License](#), which permits unrestricted use and redistribution provided that the original author and source are credited.

Selection and Peer-review under the responsibility of the NaSSiP 6 Conference Committee.



appearance, limiting oral functions, disturbing stomatognathic systems, health and psychology. Those problems could be prevented by denture replacement [4,5].

Patients with profession which demand good appearance usually do not wish edentulous period to happen, hence immediate denture treatment is indicated [6,7]. Immediate denture is a denture fabricated to immediately replace teeth following tooth removal. It is an effective transition from natural tooth to artificial tooth. There are two types of immediate dentures, those are the conventional immediate denture (CID) and the interim immediate denture (IID). The IID is usually used temporarily because of multiple anterior and posterior tooth extractions that compromised denture retentions and stabilizations. The relining is needed during healing period and must be replaced by the new denture after the mucosa is completely healed. Meanwhile CID is the type that need to be refitted by relining / rebasing only after healing period and bone formation was completed, hence more practical and economical compared to IID. The CID is indicated when only anterior teeth, sometimes include only premolar teeth extractions [8]. Both types will improve facial appearance, correct jaw relations and habitual oral functions, minimizing edentulous effects, guiding alveolar ridge form, reduce post-operative pain and bleeding [7–9].

Immediate dentures treatment is different from conventional denture treatment

because several conditions that exist may complicate the treatment. Those are tooth positions and mobility, inability to denture try-in, increased post-insertion service and the needs of post-insertion relining or rebasing [7,10]. Immediate denture treatment may be unpleasant to the patient if it is not well executed. It needs good communications, clinical techniques and laboratory procedures to achieve successful immediate denture treatment [6,10].

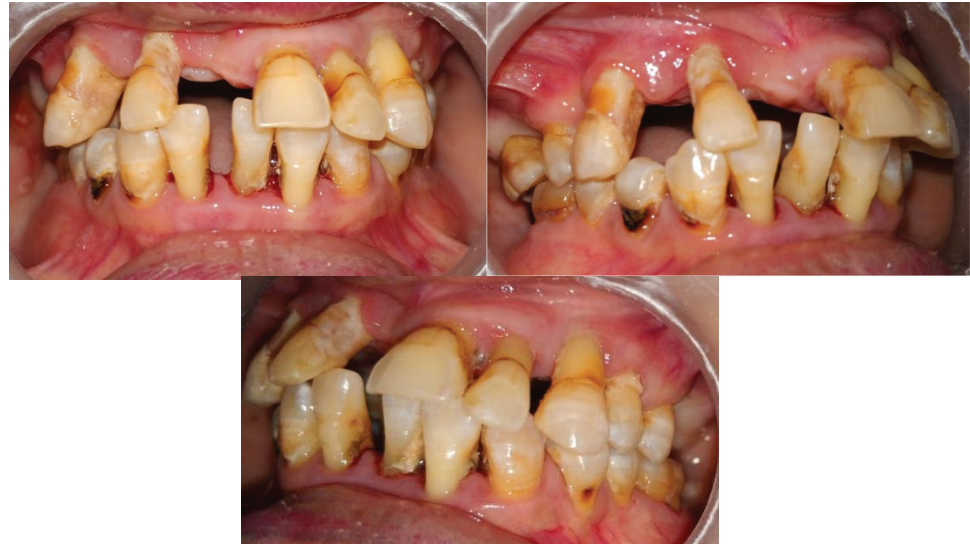**Objectives.** The aim is to observe immediate denture as a prosthetic rehabilitation treatment to replace periodontally hopeless teeth

## 2. Methods and treatment results

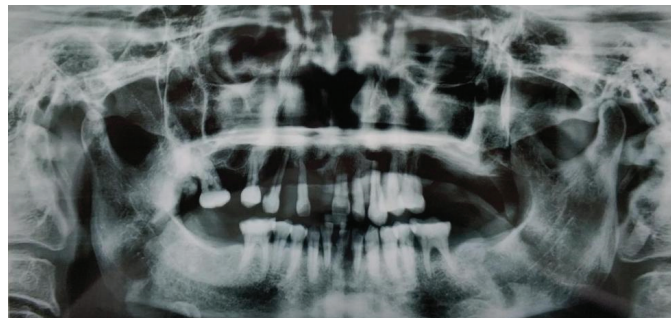A 48 years old female patient worked as a waitress and a choir singer, visited UGM dental hospital. She complained that most of her teeth were mobile and longer than before. She felt difficult in chewing and speaking. Her current conditions make her not confident to smile. Systemic health was confirmed healthy. Intraoral examinations showed poor oral hygiene, missing tooth 16, 14, 11, 26, 27, 37, 41, 47, extrusion and grade III mobility on tooth 13, 12, 21, 22, 23, 24, 32, 31, 42 (**fig.1**). Panoramic radiography revealed vertical and horizontal bone loss (**fig.2**). The diagnosis were generalized severe chronic periodontitis

with extrusion and grade III mobility on 13, 12, 21, 22, 23, 24, 32, 31 dan 42 with hopeless prognosis, associated with missing tooth 16, 14, 11, 26, 27, 37, 41, 47.

The treatment plan were extractions of maxilla and mandibula hopeless teeth (13, 12, 21, 22, 23, 24, 32, 31, 42) and replacement with acrylic resins conventional immediate partial dentures.



**Figure 1:** Initial conditions of the patient teeth and occlusions. Anterior view (a), lateral right (b) and left (c).

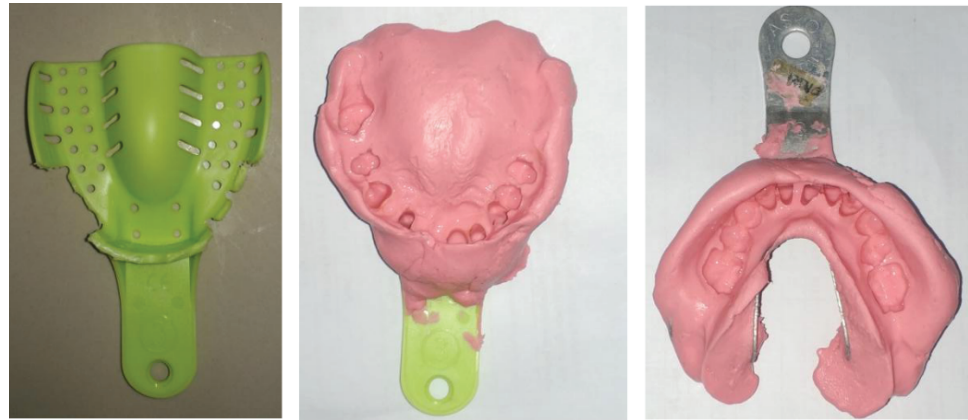

**Figure 2:** Panoramic radiographic examinations of the patient.

Informed consent was signed before treatment. The procedures consist of six clinical appointment which took two months in total. Treatment was started with impression taking, facial and dental analysis, centric relations registrations, tooth extractions and immediate denture insertions. Post-insertions recall were one day, one week and one month after denture insertions.

Since maxillary tooth was severely elongated, malpositioned and mobile, slight modifications was done during impressions taking. Impressions was done using hydrocolloid-irreversible materials (**fig.3b and c**). Maxillary tray were modified by cutting the anterior flange (**fig.3a**). To reduce iatrogenic tooth extractions, maxillary and mandibula tooth

undercuts was blocked-out with flowable composite and impressions was poured twice to make diagnostic and working cast.



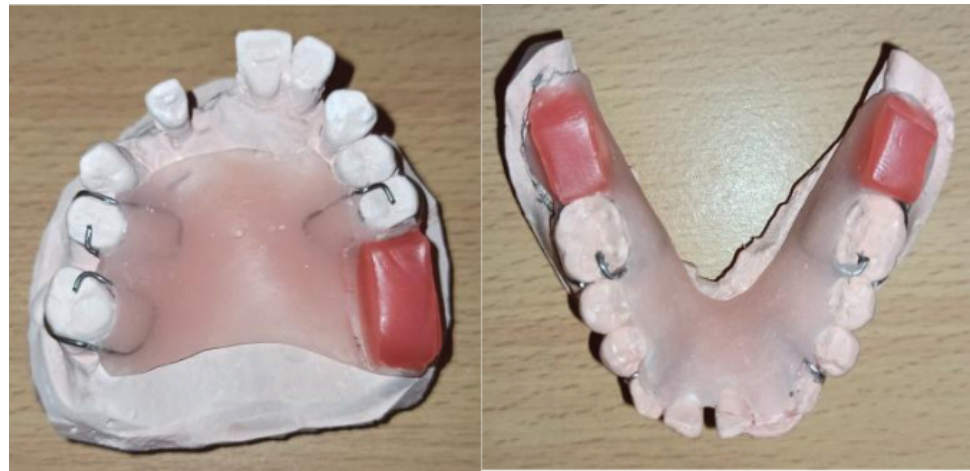**Figure 3:** Modifications of maxillary tray (a); Impression taking using hydrocolloid irreversible materials (b and c).

The midline positions was confirmed by anatomic landmarks such as philtrum, labial frenum, incisive papilla and palatal suture. Width of ala nasi was measured as a guide for tooth size and cuspid position. Tooth color was confirmed using Vitapan shade guide (A3). Denture supports was obtained from tooth and mucosa. Direct retainers was C-clasp with occlusal rest modifications on 15, 17, 25, 36, 46 and C-clasp with cingulum rest modifications on 33 and 43. Those clasps was made from 0,7 mm wrought wire. Anterior flange was designed for maxillary denture due to defects in the anterior region. Mandibular denture was designed with non-flanged anterior.

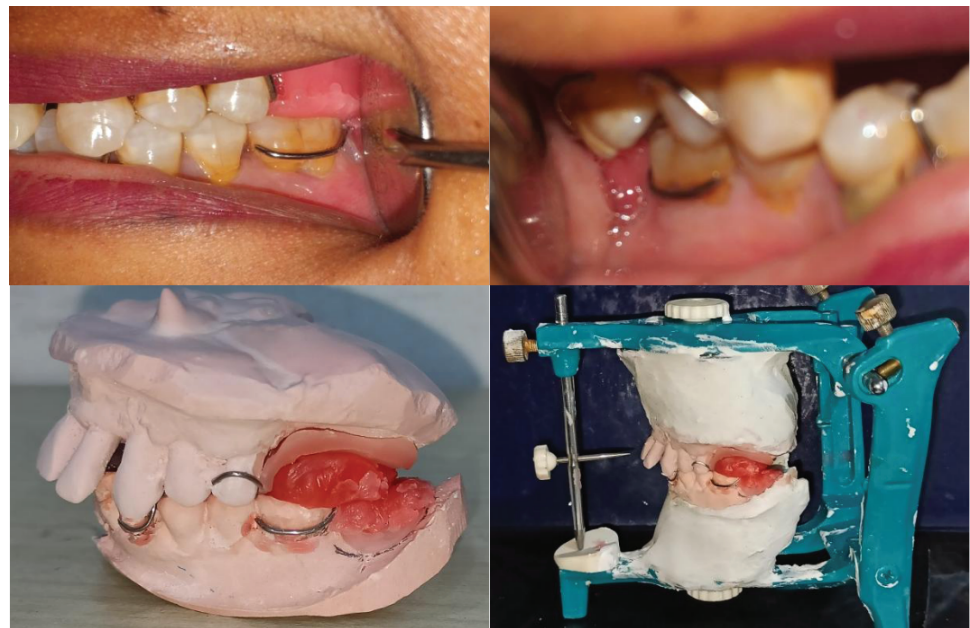
Temporary baseplate with bite record (Cavex modelling wax) was fabricated to register the centric occlusion (**fig 4**). Patient's centric occlusion was confirmed by swallowing method. After centric positions was confirmed, bite record was softened and the patient was asked to bite (**fig. 5 a-c**). The operator reconfirmed the centric occlusions. If any deviations was founded, bite record was resoftened and procedures were repeated. Correct bite record was then transfered to the working casts and mounted to the average value articulators (Meddesy) (**fig. 5d**).

Cast modifications (**fig. 6**) was carefully done to avoid overreducing that will cause mucosa binding of the denture. To prevent overreducing, spatial modelling methods was used by removing the tooth until gingival margin, buccal and lingual cast reductions and rounded the papilla.

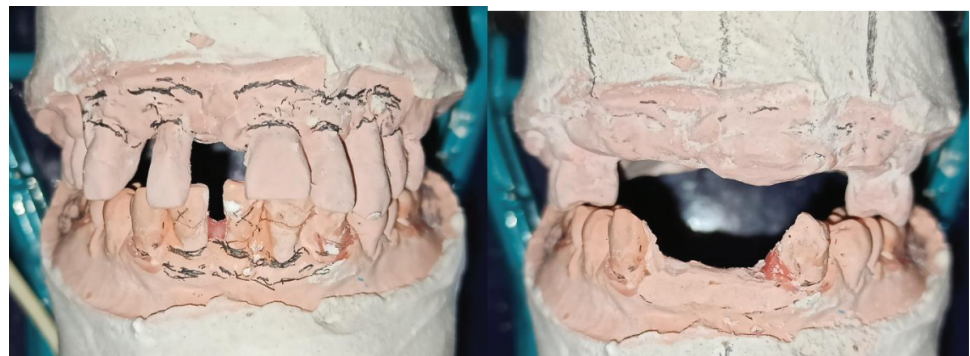
Artificial teeth were set up following the midline and the cuspid positions which were marked on the cast. Overjet and overbite were created to the normal value (2 mm). Denture processing was done after wax contouring.



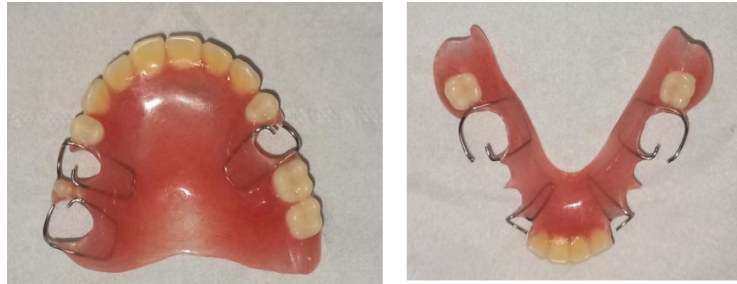**Figure 4:** Temporary baseplate with bite record to record centric occlusion.



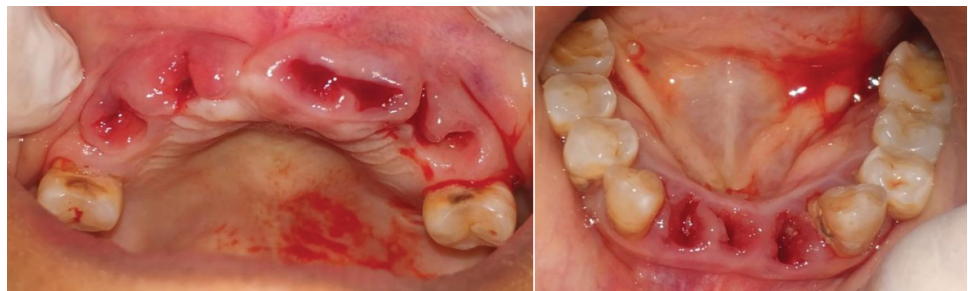**Figure 5:** Patient was instructed to bite on softened bite record (a and b); Registered occlusion was then transferred to the working model (c); Articulator mounting of the working model (d).



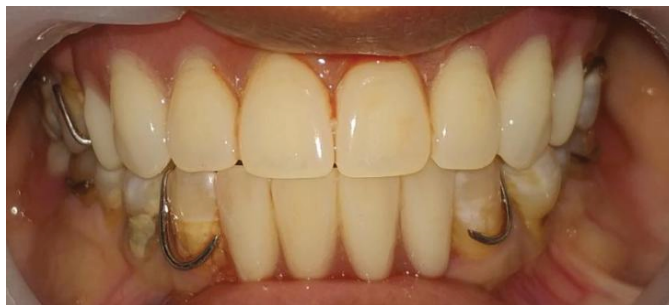**Figure 6:** Cast modifications planning (a); after cast modifications (b).



**Figure 7:** Maxilla and mandibula immediate denture.



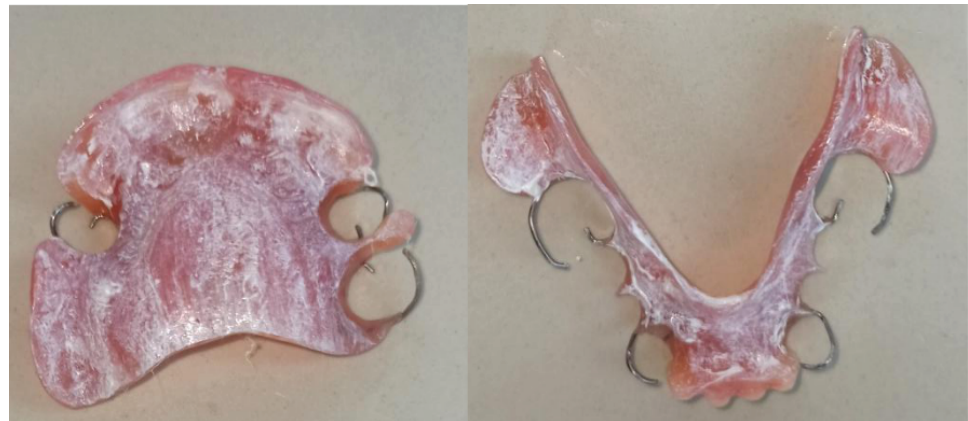**Figure 8:** Maxilla (a) and mandibula (b) teeth extractions.



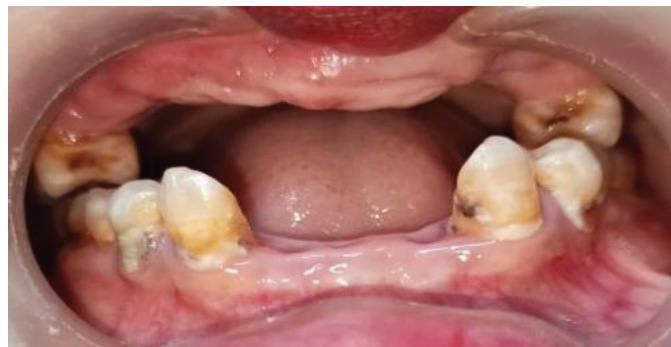**Figure 9:** Immediate denture insertions.

Before insertions, the denture was prepared by cleaning it with soap and water, and immersed in 0,05% chlorhexidine solutions for one hour. Tooth extractions procedures was started by wiping the surgical area with povidone iodine solutions. Extractions was done with local anesthesia (Pehacain<sup>®</sup>) in the vestibulum area (**fig. 8**). After tooth was extracted, surgical site bleeding was controlled by pressing with wet sterile gauze for a while and denture was immediately inserted (**fig.9**). Retention, stabilization and occlusion was checked and adjusted. Patient was given antibiotics (amoxicillin 500 mg) three times a day for five days and NSAID (mefenamic acid 500 mg) to be consumed only if pain was felt. Patient was instructed not to remove the denture 24 hours following insertions, avoid hard and hot foods, performing oral hygiene.

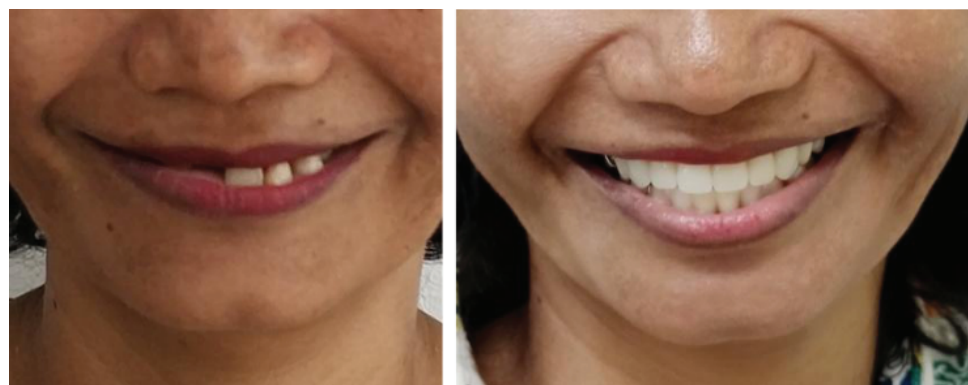At the first day post-insertion appointment, the patients felt that the pain was mild yet she could eat and speak better than before. The denture was removed and extractions



**Figure 10:** Pressure indicating paste on the denture fitting surface indicate any excessive mucosa impingement to the mucosa.



**Figure 11:** Mucosa healing one month post-insertion.



**Figure 12:** Comparations of patient smile before (a) and after (b) immediate denture treatment.

site was examined. Debris was cleaned using saline solutions irrigations. Healing was good and there were no sign of bleeding. The fitting surface was checked for any traumatic contact using pressure indicating paste (PIP (**fig.10**)). Occlusion was checked and adjustment was made. Patient re-evaluated one week and one month later.

First week and one month control (**fig.11**) shows that the denture was performing well, mild traumatic contact on the fitting surface was confirmed using PIP and was

readjusted. The patient was reminded that the denture might need relining or replacement in the future because of on going bone resorption and remodelling. The patient was encouraged to be evaluated six months later. Overall, the patient was satisfied with the treatment results. She gained back her confident to smile, talk and eat with the new denture (**fig.11**).

### 3. Discussion

This case presented a patient who had severe chronic periodontitis with hopeless prognosis (13, 12, 21, 22, 23, 24, 32, 31, 42 ) which need to be extracted. She denied edentulous period in the anterior teeth regions because of her professions., so the conventional immediate partial denture treatment was chosen. By considering her financial status and the treatment prognosis of this case, CID type of immediate denture was selected instead of IID type. Immediate denture will restore facial appearance, protect wounds, enhance healing, and correct wrong habitual oral functions. It will also guide the alveolar ridge form [9,10].

Modifications in impressions procedures are needed to avoid complications such as iatrogenic tooth extractions. Preliminary and functional impressions are usually needed to fabricate immediate denture. Some suggested to use modified tray and elastomeric materials [8,11,12]. Those require two times of impressions, which may be not efficient and may increase the risk of iatrogenic extractions. The other method suggested only once impressions by blocking tooth undercuts, using hydrocolloid irreversible material and poured the impressions twice with dental stone to produce diagnostic and working cast [13]. In this case, impressions were done by blocking tooth undercuts with flowable composite because its ease of use and could be removed easily, impressions using modified tray and hydrocolloid irreversible materials, and pouring the impressions twice to make two cast.

Registrations of centric occlusion is very important. Posterior registration using wax cone is recommended. Elastomeric bite registrations materials is not recommended because of its flexibility [8]. Cast were mounted and modified. Cast modifications was carefully done to avoid insertions complication and excessive mucosa pressure. In this case, spatial modeling method was used because it is a method invented to avoid radical alveoloplasty. Other commonly used methods were Jerbi method and Standard method which reduce the cast more aggressive and often cause mucosa binding that could hinder insertions [14]. After modifications, tooth were then set up by considering its appropriate size, locations and color [8].



To avoid infections, denture should be cleaned and disinfected before insertions. It is recommended to wash it with soap and immersed it in antiseptic solutions for at least one hour prior insertions. During extractions, the anesthetic sites should be located slightly away from the gingiva to prevent insertions complications due to the ballooning of the mucosa by anesthetic solutions [8,10].

Immediate denture was inserted immediately after teeth were extracted. Retention, stability and occlusion were evaluated and adjusted. Phonetics was evaluated while the patient was talking. The patient was instructed to not remove the denture for 24 hours and come back again 24 hour later [8,10]. Insertions result showed good retention and stability. Minor occlusal discrepancies were founded and adjusted. Artificial teeth form, color, size and arrangement was harmonious with the patient existing teeth. They created a pleasant smile line to the patient.

Retentions, support and stability were re-evaluated 24 hours post-insertions visits. Retentions and stability depend on impressions, cast modifications and occlusions. Occlusion discrepancies will cause soft irritation to the mucosa. Any mucosa impingement should be detected and corrected using pressure indicating paste

(PIP) [8]. In this case, 24 hours recalls showed that the wound was healing and no bleeding was founded. Minor occlusal adjustment was made. Fitting surface assesment using PIP showed some areas with excessive pressure, hence surface reductions were carried out. Retention, stability, esthetics and phonetics was acceptable. Patient was instructed to clean the denture and removed it at night.

Periodic recall is advised because extraction socket healing and ridge formations need several weeks to months. Some suggest patient to come again 2 – 3 weeks and 3 – 6 months. Inflammations, retentions and stability should be checked and corrected in every visits. Relining or rebasing are suggested 3- 6 months after insertions. Fabricating a new denture is advised after 2 years [10,15]. In this case, patient had been evaluated one weeks and one months after insertions. One week evaluations result showed good mucosa healing, good retention, stability and occlusions. Mild mucosa irritation was founded and the fitting surface was adjusted One month evaluation showed the patient had adapted to the denture. No signs of mucosa irritations and denture instability were founded.

Patient admit that immediate denture treatment has improved her quality of life. She could work and socialize following teeth extractions and denture insertions. She felt more confident because her profile appearance, speaking and chewing ability are all improved. Objectively, the denture has acceptable retention, stability and occlusion.

Analysis of the patient smile before and after treatment shows that the patients could smile wider, which showed that the patient was satisfied with the results.

## 4. Conclusions

Immediate denture can be considered as a predictable treatment to replace hopeless teeth, which will restore esthetics, occlusions and speech with satisfactory retention and stabilization.

## References

- [1] Newman MG, Takei HH, Klokkevold PR, Carranza FA. Carranza's clinical
- [2] periodontology. 11<sup>th</sup> ed. China: Elsevier Saunders; 2012.
- [3] Lertpimonchai A, Rattanasiri S, Arj-Ong Vallibhakara S, Attia J, Thakkinstian A. The association between oral hygiene and periodontitis: A systematic review and meta-analysis. *International Dental Journal*. 2017;67(6):332–43.
- [4] Nemcovsky CE. Evidence-based decision making in periodontal tooth prognosis. *Clinical Dentistry Reviewed*. 2017;1(3):1–11.
- [5] Emami E, De Souza RF, Kabawat M, Feine JS. The impact of edentulism on oral and general health. *International Journal of Dentistry*. 2013;2013(1):1-7.
- [6] Kossioni AE, Dontas AS. The stomatognathic system in the elderly. Useful information for the medical practitioner. *Clinical Interventions in Aging*. 2007;2(4):591–7.
- [7] Hasti K, Hasti A, Sharma R, Mitra A. Immediate denture – An important treatment modality. *Kerala Dental Journal*. 2016;39(1):26–9.
- [8] Basker RM, Davenport JC, Thomason JM. Prosthetic treatment of the edentulous patient. India: Wiley-Blackwell; 2011.
- [9] Zarb G, Horbkik JA, Eckert SE, Jacob RF. Prosthodontic treatment for edentulous patients. 13<sup>th</sup> ed. United states: Elsevier Mosby; 2013.
- [10] Carr AB, Brown DT. McCracken's removable partial prosthodontics. 12<sup>th</sup> ed.
- [11] Canada: Elsevier Mosby; 2011.
- [12] Kraljevic S, Panduric J, Badel T, Celic R. Immediate complete denture
- [13] prosthetics. *Acta Stomatologica Croatia*. 2001;35(2):281–5.
- [14] Lee H, Park C. A method to make a preliminary impression of mobile teeth. *The Journal of Prosthetic Dentistry*. 2009;102(1):52–3.

- [15] Lampraki E, Chochlidakis KM, Rossopoulos E, Ercoli C. An alternative impression technique for mobile teeth. *Journal of Prosthetic Dentistry*. 2016;116(4):492–5.
- [16] Puthanakar NY, Pappachan B, Patil AG. Full mouth rehabilitation by immediate denture prosthesis - A case. *Annals and Essences of Dentistry Journals*. 2012;4(4):28–33.
- [17] Phoenix RD, FLeigel JD. Cast modification for immediate complete dentures:
- [18] Traditional and contemporary considerations with an introduction of spatial modelling. *Journal of Prosthetic Dentistry*. 2008;100(5):399–405.
- [19] Caputi S, Murmura G, Ricci L, Varvara G, Sinjari B. Immediate denture fabrication: A clinical report. *Annali di Stomatologia*.2013;4(3–4):273–7.