



Research article

Crown Lengthening for Obtaining Biological Width in Dental Restoration: A Case Report

Adinda Ramadianti Fitria¹, Dimas Ilham Hutomo^{2*} and Hari Sunarto²¹Periodontics Resident, Faculty of Dentistry, Universitas Indonesia, Jakarta, Indonesia²Department of Periodontics, Faculty of Dentistry, Universitas Indonesia, Jakarta, Indonesia**Abstract.**

Background: Biological width is a natural defensive space for periodontal tissue which is important for maintaining healthy periodontal tissue so that it can support the success of dental restoration treatment. The localized alveolar bone loss, gingival recession, localized gingival hyperplasia or a combination of all three can be caused by poor biological width restoration. Biological width is obtained through crown lengthening when restoration of teeth have caries or subgingival fractures under the gingival attachment. The crown-lengthening procedure is performed to increase the height of the clinical crown for restoring and improving the esthetics of the teeth.

Objective: This case report presents two cases of crown lengthening with osteotomy before the dental restoration procedure.

Case Report: The first case was of a 43-year-old woman who was referred from the prosthodontics clinic RSKGM FKG UI before making permanent restorations on tooth 13. Clinical examination showed red gums, swelling and caries that extended to subgingival especially in the distal part. A crown-lengthening procedure with an osteotomy was performed distally to increase the height of the clinical crown so that it had a good ferrule effect for the restoration of the tooth. The second case was of a 25-year-old female patient who had undergone root canal treatment by a general dentist. The clinical appearance of the tooth showed an imbalance in the height of the gingival zenith with the tooth next to it, and the clinical crown looked short. Crown lengthening with osteotomy was done to get a balanced zenith height.

Conclusion: Crown lengthening is a periodontal surgical treatment performed to obtain optimum biological width to support tooth restoration.

Keywords: crown lengthening, osteotomy, biological width

Corresponding Author: Dimas
Ilham Hutomo; email:
dimas.hutomo@ui.ac.id

Published: 25 April 2022

Publishing services provided by
Knowledge E

© Adinda Ramadianti Fitria et al. This article is distributed under the terms of the [Creative Commons Attribution License](#), which permits unrestricted use and redistribution provided that the original author and source are credited.

Selection and Peer-review under the responsibility of the NaSSIP 6 Conference Committee.

1. Background

Periodontal tissue health of the restored teeth is necessary for the long term. Dentists must be able to pay attention to the restorative and aesthetic results on the health of periodontal tissues.(1) Dental esthetics are the main consideration for patients seeking restorative care.(2) The esthetic smile design is based on the white and pink aesthetics that are connected by the face, lips, gingiva, and teeth.(3) Gingival health is one of the aesthetic goals during treatment planning. Gingival morphology, lines and contours have an important role to get optimal aesthetics. Gingival aesthetics are formed from

OPEN ACCESS

the position and peak of the gingiva. Zenith gingiva (ZG) is the most apical form of free gingival margin. The gingival line (GZL) is defined as a line connects the tangent line of the gingival zenith of the central incisors and canines.(2) Placement of the restorative margin in supragingiva, makes it possible to facilitate the insertion of restorations, cleansing, and caries detection secondary.(1) Periodontal tissue health and dental restoration are interrelated. There are still many dentists who cannot make practical use of the concept of biological width in perio-restorative.(4) Perio-restorative procedures require the principle of biological width as clinical guidelines.(5) Supragingival tooth structures

repaired for restorative or aesthetic purposes require crown lengthening. This procedure is usually used to improve tooth structure when the available clinical crown is inadequate for restoration placement and obtaining esthetics.(6) Dentists need crown lengthening in dentistry to consider how to best deal with the biological, functional and aesthetic needs of each particular case.(7)

Crown lengthening is one of method to improve tooth structure and facilitate restorative therapy in caries or extensive and subgingival fractures.(8) Increased plaque accumulation in restoration with equigingival and subgingival margins, can potentially lead to more severe gingival inflammation followed by periodontal damage with increased pocket depth, attachment loss, and gingival recession.(9) Gingival inflammation, attachment loss, and bone loss can be caused by the restorative margin being within the biological width. Microbial plaque located in deep periodontal pockets or gingival recession causes a destructive inflammatory response.(10)

2. Case 1:

2.1. Clinical history and findings

A 43-year-old woman was consulted from the prosthodontics clinic RSKGM FKG UI to do crown lengthening before making a permanent restoration on tooth 13. Clinical examination showed hyperemia gingiva, swelling and caries that extend to subgingiva, especially in the distal part. Patients brush their teeth twice a day, morning after breakfast and at night before bed. When there is food slip, the patient uses a toothpick and the patient uses mouthwash. The tartar cleaning was last performed in September 2019. The patient does not smoking and denies having systemic disorder. General clinical examination showed good oral hygiene scores, gingiva hyperemia and recession, depth

of the periodontal pocket of the distopalatal tooth 13 was 4 mm, adequate keratinized gingiva, no tooth mobility.

During the first visit, bone sounding was also measured to determine the distance of the alveolar crest to the gingival margin, bone sounding on distal and mid palatal tooth 13 was 4 mm. Radiographic examination of tooth 13 (Figure 1c). Based on the results of clinical and radiographic examination, the patient was diagnosed with a short clinical crown on tooth 13.

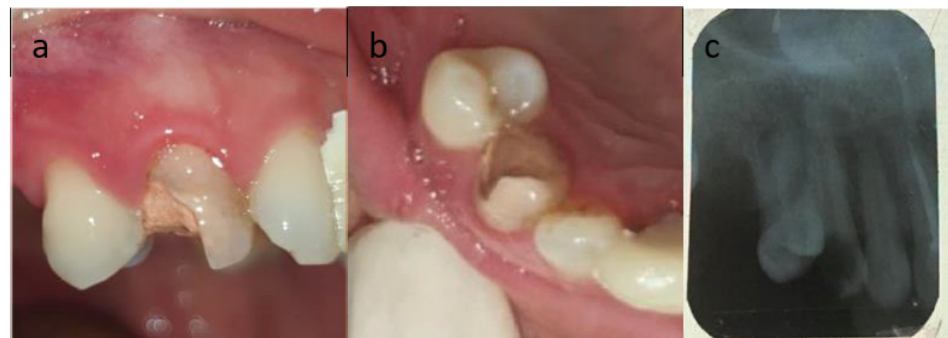


Figure 1: a. Initial intra oral clinical condition showing tooth 13 having a vertical crown fracture with the fracture edge below the gingival margin; b. Dental examination 13 on the palatal surface; c. Radiographic examination of tooth 13.

2.2. Case management

During the first visit periodontal therapy was carried out in the form of a complete periodontal examination, scaling and oral hygiene instructions. Patients are planned for crown lengthening after evaluation of improved oral hygiene. The patient was checked for oral hygiene and given informed consent at the time of surgery. After evaluation of approximately one month with a good oral hygiene score, patients were crown-lengthening with a 2 mm disto palatal surface gingivectomy technique from the gingival margin followed by a full thickness intrasulcular incision on the palatal surface of teeth 14-12.

Ostectomy bone reduction of about 2 mm on the distal surface of tooth 13 by using a round bone with a low speed followed by irrigation and continued bone refinement osteoplasty to form a good bone topography with bone file and chisel. The flap adaptation is then performed on the reduced bone surface. Vertical external mattress suture technique with nylon 5.0 was used on this. Patients were prescribed 500 mg of amoxicillin antibiotics and 500 mg of

mefenamic acid analgesics accompanied by a 0.2% minosep mouthwash and described after surgical instructions.

One week after the operation, the gingiva was still seen to be inflammatory and hyperemia. Sutures were removed on two-weeks, slight hyperemia and edema on post-surgical site were found. One month after surgery there are no signs of inflammation. Patient returned to Prosthodontics for a dowel crown.

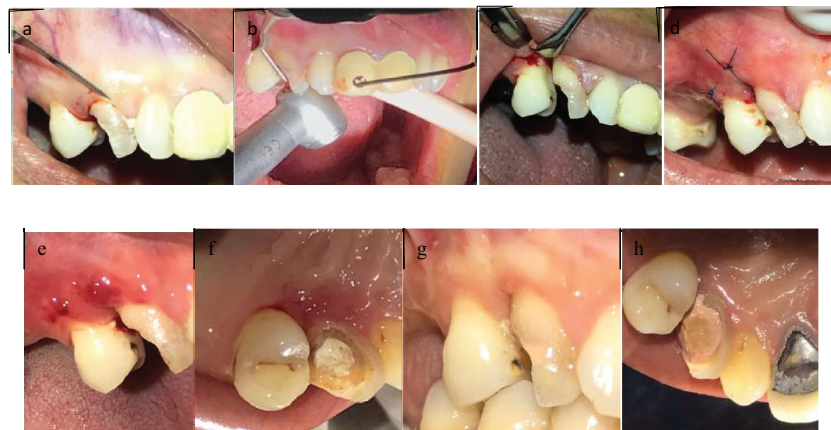


Figure 2: a. Sulcular Incision; b. Crown lengthening; c. Osteotomy; d. Suturing; e. aff hecting; f. control 2 weeks, palatal 13; g. control 1 month; h. control 1 month, palatal 13.

3. Case 2:

3.1. Clinical history and findings

Female patients aged 25 years were referred by general dentists after root canal treatment. On clinical examination found zenith gingival tooth 14 more to coronal, has a high lip line and tooth 14 exposure when smiling. Generally good oral hygiene, keratinized tissue 6 mm, bone sounding in mesiobuccal and distobuccal 4 mm and midbuccal 3 mm. The patient does not smoking and denise having systemic disorder. The clinical appearance of the tooth shows an

imbalance in the height of the gingival zenith with the tooth next to it, and the clinical crown looks short. Crown lengthening with osteotomy is done to get a balanced zenith height.

3.2. Case management

During the first visit periodontal therapy was carried out in the form of a complete periodontal examination, scaling and oral hygiene instructions. Patients are planned for crown lengthening after evaluation of improved oral hygiene. The patient was checked

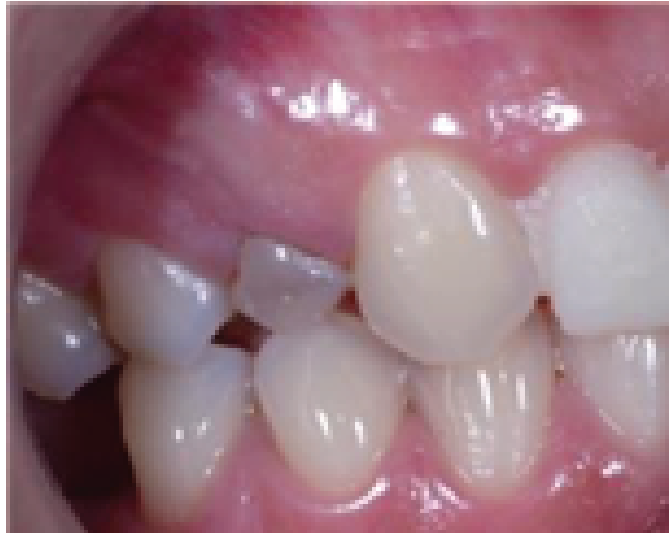

Figure 3: Clinical appearance of tooth 14.

for oral hygiene and given informed consent at the time of surgery. Tooth 14 performed gingivectomy by 2 mm then osteotomy by 2 mm. Preparation is done 10 weeks after crown lengthening and crown insertion after 12 weeks after crown lengthening.

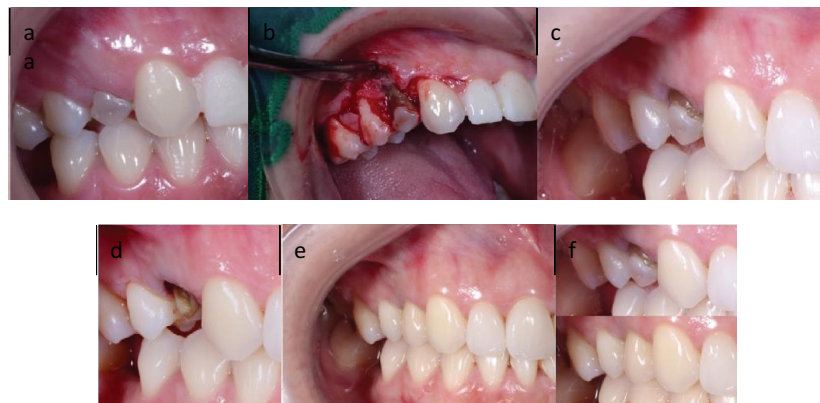

Figure 4: a. Clinical appearance 14; b. Crown lengthening and osteotomy; c. control 3 weeks after crown lengthening and osteotomy; d. After crown preparation; e. After crown insertion; f. Before-after appearance.

4. Discussion

The concept of biological width originated from a study by Gargiulo et al., which measured the dimensions of the average epithelial junction (0.97 mm) and connective tissue attachment (1.07 mm) to provide an average biological width 2.04 mm. The concept of biological width is a necessary step, in restorative and prosthetic rehabilitation, to obtain and maintain healthy soft tissue.(11) Crown Lengthening is a surgical procedure

that requires adequate tooth structure lengthening for a restoration procedure. Various techniques and methods used in crown lengthening must be performed in such a way as to avoid biological width violation that can have adverse effects on periodontal tissue that cause gingival inflammation, attachment loss and alveolar resorption.(7)

The purpose of crown lengthening is to provide adequate clinical crowns when restorative to restore optimal tooth shape. Crown lengthening indications are subgingival caries, subgingival fractures, teeth with extensive caries or fractures, short clinical crowns.(7) Some conditions that need to be identified and analyzed such as gingival tissue position, alveolar bone height and clinical crown length are determinants for identifying crown lengthening. Crown lengthening techniques can be performed such as gingivectomy, apically positioned flap with or without osseous resection and orthodontic extrusion.(12)

Gingival length of more than 3 mm, apical to the gingival margins of the upper teeth, can cause unwanted "sweet smiles". If only soft tissue cutting is needed (without bone resection), there are two choices; gingivectomy (beveled incision) or flap that is positioned apically (reverse bevelled incision). Bone resection is required using a full-thickness flap, if the alveolar crest is less than 3 mm.(13) The method chosen depends on the following factors, such as aesthetics, root-root proportion, root shape, furcation involvement, tooth position, tooth keratin height, and final restoration estimation.(12) Clinical crown lengthening is performed to achieve margins in healthy tooth structure, maintenance of biological widths, access to impression

techniques, and aesthetics.(14) In the first case needed a gingivectomy and an ostectomy 2 mm to obtain the ferrule effect. According to Lima et al., successful post endodontic restoration requires a ferrule effect of at least 1.5 mm.(15)

Restoration and dowel crowns were made after 4 weeks of control of gingivectomy and ostectomy on first case. In the second case, restoration were made 10 weeks after crown lengthening and crown insertion after 12 weeks after crown lengthening. The gingival contour has been formed and the margin of the crown is placed intracrevicularly atraumatically, definitive restoration can be placed successfully within 8-12 weeks after crown lengthening. According to Fletcher, osseous remodeling can continue for more than 12 months, and soft tissue healing is mostly completed in eight weeks. Lanning et al., And Shobha et al., Said that at least a period of at least six months is required for the reestablishment of biological width after crown lengthening. In the research Herrero et al., And Bragger et al., Also said that although there was a change in the position of the gingival margin, the probing depth and attachment level would be stable within 3 months, and it would take a minimum of six months to restore the biological width.(5)

Failure crown lengthening with the above treatment are divided into early (before placing the restoration) and late or delayed (after restorative procedures) failures. Early failures include coronal returning of the gingival tissue on the tooth structure, absence of adequate keratinized gingiva around the tooth, presence of granulation tissue in the coronal areas of tooth structure and not creating an adequate distance between the bone crest and the tooth margin. Late failures are mainly due to the impingement of the restoration on the biologic space.

A study by Lanning et al evaluated the success of crown lengthening procedures and re-establishment of the biologic width and showed that 90% of the areas treated required osteotomy of 3 mm or higher.

The results of restoration without repairing healthy gingival tissue will have a negative impact on someone smiling. Therefore, forming the gingival aesthetic is an important component of a beautiful smile design.(3) In the second case, 2 mm reduction in gums was made to equalize the gingival zenith because the patient had high lip line and exposed tooth 14 when smiling.

Zenith is defined as the most apical point of the gingival marginal scallop. Gingival Zenith Position (GZP) of the maxillary anterior teeth and Gingival Zenith Level (GZL) of lateral incisors relative to the central incisors and canines can significantly influence the aesthetic appearance of a smile.(2) Zenith relative gingiva and gingival margin contour height are important parameters from an aesthetic point of view. Irregular gingival contours can significantly affect the appearance of natural and prosthetic teeth. The zenith point orientation is distal to the long axis of the central incisors and canines, and coincides with the long axis of the lateral incisors. The gingival margins of the central incisors and canines must be at the same height.(16) It is desirable to have a gingival tissue elevation of the lateral incisors with 1 mm incisal with gingival margins of the central incisors and adjacent canines. Correct orientation of the peak contour and gingival height after therapeutic manipulation is important because it helps avoid gingival level disharmony and helps in determining the correct proportion of teeth. Zenith gingiva can also help in forming the desired axial inclination of the tooth if the angular position of the long axis of the tooth is modified.(16) Touati said that each anterior maxillary tooth had a certain aesthetic role, namely the central incisors provided stability and balance, the lateral incisors provided charm, and the canines added aesthetic.(17)

5. Conclusion

Crown lengthening is a periodontal operation that is commonly done in dentist practice to improve tooth structure and facilitate restorative therapy in caries or extensive and subgingival fractures. In the first case, gingivectomy and ostectomy were performed to obtain biological

width and restore margins due to subgingival caries. In the second case gingivectomy and ostectomy were performed to obtain biological width and adjust the zenith. A comprehensive examination that includes clinical examination, radiographic examination, and analysis of the diagnostic role is very important for the success of rehabilitation.

References

- [1] Lanning SK, Waldrop TC, Gunsolley JC, Maynard JG. Surgical crown lengthening: Evaluation of the biological width. *J Periodontol.* 2003;74(4):468–74.
- [2] Humagain M, Rokaya D, Sri R, Dixit S, Kafle D. Gender based comparison of gingival zenith esthetics. *Kathmandu Univ Med J.* 2016;14(54):148–52.
- [3] Devapriya Appukuttan, Priyanka K. Cholan CRA, Swapna S. Assessment of gingival zenith position and distance from vertical bisecting midline in the maxillary anterior dentition – An observational study abstract. *J Orofac Sci.* 2018;10(Jul):14–8.
- [4] Parashar A, Zingade A. Biological width: The silent zone. 2015;2(4):11–6.
- [5] Nautiyal A, Gujjari S, Kumar V. Aesthetic crown lengthening using Chu aesthetic gauges and evaluation of biologic width healing. *J Clin Diagnostic Res.* 2016;10(1):ZC51–5.
- [6] Quiñones JA, Salinas RG, Fierro C et al. Crown lengthening procedure using aesthetic measurement gauges: A case report. *Int J Appl Dent Sci.* 2017;3(2):95–7.
- [7] Gupta G, Gupta R, Gupta N, Gupta U. Crown lengthening procedures- A review article. 2015;14(4):27–37.
- [8] Hempton TJ, Dominici JT. Contemporary crown-lengthening therapy: A review. *J Am Dent Assoc.* 2010;141(6):647–55. <http://dx.doi.org/10.14219/jada.archive.2010.0252>
- [9] Schmidt JC, Sahrman P, Weiger R, Schmidlin PR, Walter C. Biologic width dimensions - A systematic review. *J Clin Periodontol.* 2013;40(5):493–504.
- [10] Thomas S, Sampat P, Agarwal S, Prabhu A, Pathak T. Biologic width – Exploring the mystery of a silent zone. 2018;17(12):38–45.

- [12] Marzadori M, Stefanini M, Sangiorgi M, Mounssif I, Monaco C, Zucchelli G. Crown lengthening and restorative procedures in the esthetic zone. *Periodontol 2000*. 2018;77(1):84–92.
- [13] Pham HT, Nguyen PA, Pham TAV. Periodontal status of anterior teeth following clinical crown lengthening by minimally traumatic controlled surgical extrusion. *Dent Traumatol*. 2018;34(6):455–63.
- [14] Dholey MK, Sinha S, Kole D, Sen S. The crown lengthening surgery two case reports. *Asian Pacific J Heal Sci*. 2018;5(4):23–6.
- [15] Oh SL. Biologic width and crown lengthening: Case reports and review. *Gen Dent*. 2010;58(5).
- [16] Amin WM, Al-Huniti NS, Hasan NI, Al-Nimri DW, Al-Najdawi SA. Effect of ferrule location on fracture resistance and failure pattern of endodontically treated maxillary incisors restored with quartz fiber posts. 2013;4(Sept):343–52.
- [17] Bennani V, Ibrahim H, Al-Harhi L, Lyons KM. The periodontal restorative interface: Esthetic considerations. *Periodontol 2000*. 2017;74(1):74–101.
- [18] Konikoff BM, Johnson DC, Schenkein HA, Kwatra N, Waldrop TC. Clinical crown length of the maxillary anterior teeth preorthodontics and postorthodontics. *J Periodontol*. 2007;78(4):645–53.