



Research article

Gingivectomy as a Supportive Therapy in Orthodontic Treatment of Bilateral Cleft Lip and Palate Patient: A Case Report

Ira Komara¹ and Ifadah Ifadah^{2*}

¹Department of Periodontology, Faculty of Dentistry, Universitas Padjadjaran, Bandung, Indonesia

²Periodontist, Dental and Oral Hospital of South Sumatra Province, Palembang, Indonesia

Abstract.

Background: One of the congenital malformation in the early phase of embryogenesis is cleft lip and/or palate that need multidisciplinary treatment in dentistry. Although surgery is performed in the first few months of life, advanced treatment is needed sometimes in the growth age, such as orthodontic, periodontic and esthetic treatment.

Objective: To describe a gingivectomy procedure to support orthodontic treatment in bilateral cleft lip and palate patient.

Case Report: A 13-year-old boy was referred from the orthodontic department with complaints of enlargement in maxillary anterior gingiva teeth, blocking the placement of the orthodontic device. Patient's examination showed bilateral cleft lip and palate, plaque score 35%, bleeding on probing 73%, dental agenesis on teeth 12 and 22, and gingival enlargement on regions 13–23. The aim of gingivectomy, in this case, was to eliminate pockets, restore physiologic gingival contour and facilitate the placement of the orthodontic device.

Results: Clinical evaluation after gingivectomy showed satisfying results in reducing the pocket depth.

Conclusion: Gingivectomy is effective in supporting the orthodontic treatment for cleft lip and/or palate patient.

Keywords: cleft lip, cleft palate, gingival enlargement, gingivectomy, orthodontic treatment

Corresponding Author: Ifadah

Ifadah email:

ifadah.haikal@gmail.com

Published: 25 April 2022

Publishing services provided by
Knowledge E

© Ira Komara and Ifadah

Ifadah. This article is distributed under the terms of the [Creative Commons Attribution License](#), which permits unrestricted use and redistribution provided that the original author and source are credited.

Selection and Peer-review under the responsibility of the NaSSiP 6 Conference Committee.

1. Background

One of the most common craniofacial birth defects was clefts of the lip and/or palate [1,2,3]. Multi-deformity defects related to structural and functional development of oral and maxillofacial organs, these required a series of treatment beginning at birth until adolescence

period or longer depended on the severity of deformity by a multidisciplinary team approach [4,5].

The head and face development represents one of the most complex events during embryonic development, synchronized by a network of transcription factors and signaling molecules together with proteins conferring cell polarity and cell-cell interactions.

OPEN ACCESS

In mammals, the facial region develops from the facial primordia, which consists of the lateral and medial nasal prominences arising from the frontonasal process and the maxillary and mandibular processes arising from the first branchial arch. The fusion of medial nasal and maxillary prominences gives rise to the lip and primary palate, while fusion of separate palatal processes arising from the maxillary prominence gives rise to the secondary palate and occurs later during embryogenesis. These processes are known to be dependent, in part, on the migration and differentiation of neural crest cells from the neuroectoderm into the branchial arches. Interference of this closely controlled cascade can result in a facial cleft where these facial primordia ultimately fail to meet and fuse or form the proper structures [2].

The etiology is unknown, but it is considered to be complex [6]. Some cleft lips and palates have a genetic origin, others may be caused by environmental factors [2,6]. The environmental factors are heredity, maternal drug use, maternal diseases, nutrition, and maternal exogenous exposures [2].

The cleft lip and/or palate's treatment should be started right after birth [7]. Children with a cleft require multidisciplinary treatment due to problems during feeding, speaking, listening, as well as frequent ear infections and psychosocial issues [6]. The major purpose of treatment was to correct deformities and create a normal function. Current concept of treatment for normal occlusion required both orthodontic treatment and several surgical interventions such as cheiloplasty, palatoplasty, alveolar bone grafting, orthognathic surgery, distraction osteogenesis, and other surgery for correcting defects if needed [1]. The treatment can achieve a proper occlusion and function often lasts from birth until adulthood in cleft lip and/or palate patient. In the first months of life, facial surgery is preventive and interceptive

treatment, speech therapy in primary dentition, orthodontics in the mixed dentition phase, and oromaxillofacial surgery, implant, and prosthetics in adults [7].

Variations of dental anomalies in tooth number, dislocation, missing, supernumerary, tooth shape, and reduced tooth dimensions have always been found to be higher in cleft lip and/or palate patients when compared with the general population [7]. Most children have a deficiency of soft tissues, bone volume, malformation and/or lack of teeth at the cleft site [6].

Patients with cleft lip and/or palate need extensive and prolonged orthodontic treatment [7]. Orthodontic treatment provides alignment and stabilization of the teeth after reconstructive procedures [6]. Once the dentition is completed, between the ages of 10 or 15 years, would require a definitive orthodontics treatment [4,8]. Orthodontics is one of the basic pillars to create an ideal facial growth and development and excellent

dentition, the minimally aggressive surgery, and the correct timing for maxillary guidance and stimulation [4]. Comprehensive treatment between the orthodontist, surgeon, periodontist, prosthodontist, and general dentist is required [7].

Periodontal treatment should begin early and continue as supportive therapy [4]. Children and adolescents with cleft lip and/or palate are at increased risk for gingivitis, periodontitis and carious lesion [6,5,9]. Numerous factors contribute to the difficult oral hygiene are close to cleft area, including presence of frenula, tooth malposition, gingival recession, dental anomalies and extended use of fixed orthodontic appliances [6,9].

After defect closure and orthodontic appliances, the scar tissues observed hinder optimal plaque control [6,5]. Periodontal therapy should be an integral part of the total restoration of the function and esthetics of the cleft palate patient. Periodontal surgery may need to correcting the periodontal soft tissue lesion adjacent to the teeth near the cleft and contribute to poor plaque control [4]. The long-term orthodontic therapy promote an iatrogenic trauma to the periodontium. The persisting soft tissue folds before closure, which are hard to reach with conventional cleaning techniques, may serve as a habitat for putative pathogens and thereby enhance the intraoral translocation of pathogens and consequently the risk of

periodontal infections. The periodontal status in adolescents with various forms of cleft lip and/or palate shows a high incidence of plaque and bleeding on probing [6,5]. Periodontist acts for oral hygiene instruction and control, during surgical, orthodontic, and rehabilitative treatment [9].

Gingival enlargement is a gingival disease accompanied by an increase in the size of the gingiva. Gingival enlargement can occur as a result of bacteria, being carried deep into the tissues when foreign materials such as toothbrush bristle or fragments of food substance are forcefully embedded into the gingiva. Gingival enlargement is a rapidly expanding lesion which usually limited to marginal gingiva or interdental papilla. It appears as a red swelling with a smooth shiny surface which is painful and the associated teeth are sensitive to percussion [10].

Gingivectomy is indicated for gingival enlargement that persists after initial treatment. Gingivectomy is excision or removal of gingiva tissue to eliminate the pocket wall, improve the visibility and accessibility to lift the calculus, facilitate the smoothing of root surfaces, create a good environment for healing, and restore the gingival physiologic contour. Gingivectomy indications are eliminate suprabony pockets, gingival enlargement, and eliminate suprabony periodontal abscess. The contraindications are bone surgery and the base of pocket position is more apical than mucogingival junction [11].

2. Objectives

This article presents the case of gingivectomy procedure to support orthodontic treatment for bilateral cleft lip and palate patient. The aim of gingivectomy, in this case, was to eliminate pockets, restore physiologic gingival contour, and facilitate the placement of braces.

3. Methods and treatment results

A 13-years-old boy was referred from Orthodontic Department, Faculty of Dentistry, Universitas Padjadjaran, Bandung, Indonesia complaints of enlargement in maxillary anterior gingiva teeth and blocking the placement of braces. From the patient's mother, information was obtained during the pregnancy that his mother never suffered a serious illness, took drugs for a long time, smoked, or exposed to radiation. He was born on term with normal delivery. The patient didn't drink breast milk because he has complete bilateral cleft lip and palate since he was born. He didn't have a history of allergies, bleeding disorders, or other systemic diseases. He was the first child of two brothers and at the time of birth the mother was 32 and the father was 35 years of age.

The pre-surgical orthopedic treatment was obturator at his 14 days of life. The first palate surgery was performed at 6 months of age. At 2 years of age, complete closure surgery of cleft lip and palate was performed. This patient got orthodontics treatment at 12 years of age. The patient usually brushes his teeth in the morning and evening by himself. Currently, the patient attends a boarding school in Cimahi. He feels less confident with his condition. Therefore, his mother hopes for an esthetic improvement so her child can socialize with his friends.

The patient's examination showed bilateral cleft lip and palate, plaque score 35%, bleeding on probing 73%, agenesis tooth 12 and 22, and malposition teeth. The gingival assessment revealed red, edematous marginal and shiny rounded interdental papillae, stippling (-), pitting test (+). Hyperplastic and enlargement gingiva was present around region tooth 13 to 23 (Figure 1). The patient's pocket depth showed in Table 1. Radiographic analysis showed bone loss at tooth 11 and 21. The diagnosis was judged to be gingivitis mediated by local risk factors, periodontitis stage II grade A localized at region 11,21, with mucogingival deformities and conditions around the tooth 15, 11-13, 24, 32-42 (gingival excess).

Initial treatment included oral hygiene instructions, scaling, and root planing in the first meeting. The patient was instructed to brush his teeth twice a day using a mirror in

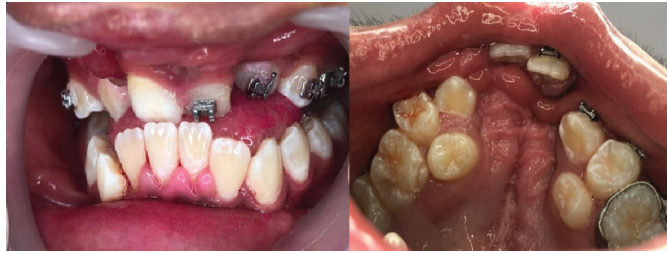

Figure 1: Labial and palatal view showing enlargement of gingiva and alveolar ridge defect.

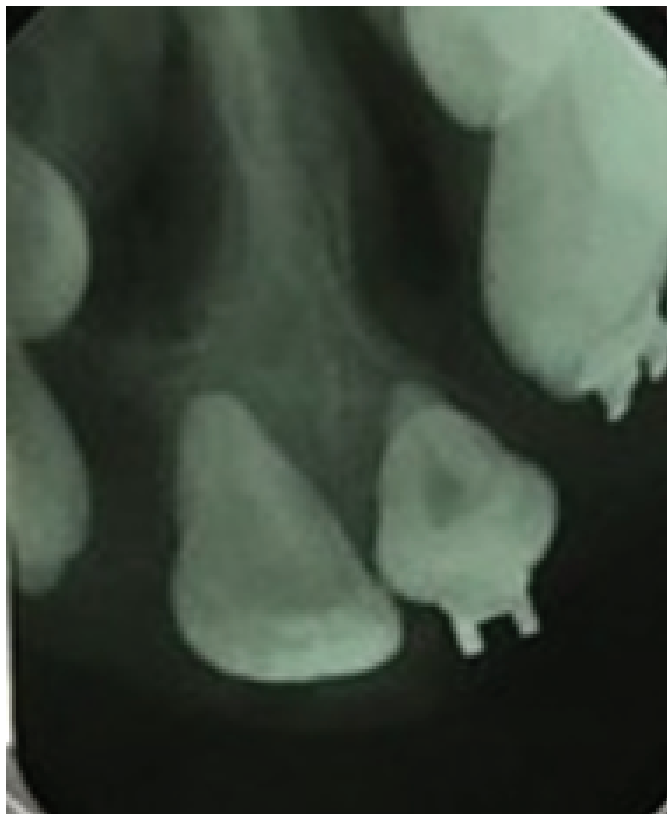


Figure 2: Occlusal radiograph showed the cleft through the palate compromising alveolar ridge and hard palate.

the morning after breakfast and in the night before going to bed. The patient was taught proper oral hygiene techniques. These consisted of appropriate brushing and flossing techniques. The patient was also instructed to use an interdental brush, floss threaders, and single tufted brushes. The oral hygiene was control a week, two weeks, and a month until ideal conditions were achieved. Once gingival inflammation was resolved and plaque score was low, the gingivectomy at region 11-13 was performed.

The surgery was performed after preparation of the patient, operator, assistant, tools and materials, and informed consent. The informed consent was signed by the patient's mother (Figure 3). Extraoral and intraoral aseptic by using 10% betadine solution. Local anesthesia by infiltration technique at surgery site (Figure 4a). The base of the pocket

TABLE 1: Patient's pocket depth.

Gigi	18	17	16	15	14	13	12	11	21	22	23	24	25	26	27	28
Facial		222	223	224	222	3210		213	323		223	422	222	213	232	
Palatal		111	121	212	112	115		9610	9105		321	121	111	Molar band	111	
Mobility		-	-	-	-	-		-	-		-	-	-	-	-	
Resesi		-	-	-	-	-		-	-		-	-	-	-	-	
BOP		+	+	-	+	+		+	+		+	-	-	-	+	

Gigi	48	47	46	45	44	43	42	41	31	32	33	34	35	36	37	38
Facial		212	222	211	212	212	224	224	425	523	321	222	323	222	222	
Lingual		221	211	111	211	213	211	111	211	111	111	111	222	211	122	
Mobility		-	-	-	-	-	-	-	-	-	-	-	-	-	-	
Resesi		-	-	-	-	-	-	-	-	-	-	-	-	-	-	
BOP		-	+	+	+	+	+	+	-	-	+	+	+	+	+	

is marked by using probe periodontal as the outline of the incision. The incision was made by #15c scalpel (Figure 4b) from the apical of point marking directly to coronal. Excision is carried out 45° to the teeth surface and as close as the bone. The aim of gingivectomy at region 11- 13 to facilitated placement of braces (Figure 4c). We found the lesion connect with labial mucosa so that after irrigated with NaCl 0,9%, the surgery site was sutured (Figure 4d). After the surgery, the patient has given instructions post surgery and a prescription of amoxicillin 3x500mg for 5 days and mefenamic acid 3x500mg prn for 5 days. Chlorhexidine 0,2% oral rinse was advised to be use by the patient twice a day for two weeks after surgery.

The patient has no complaints at one week of surgery. The operator examined the wound and removed the suture, performed oral prophylaxis and oral hygiene instruction (Figure 5).

The condition one month after surgery was patient has no complaint. The tooth pocket was decreased on 13 labial (distal: 3, mid: 2, mesial: 3) and palatal (distal:3, mid:1, mesial:3) (Figure 6).

After one month of surgery, the patient has continued his orthodontic treatment. The patient had extracted his tooth number 14 and 24. The mandibular braces have been installed. The patient came with gingivitis at three months after surgery, but the surgery site at region 11-13 has healed (Figure 7). His mother told that her son was very happy with his teeth improvement. Her child feels more confident to smile because his teeth nicer than before.

4. Discussion

The case presented a gingivectomy in a 13-years-old boy with a history of bilateral cleft lip and palate. The etiology of cleft lip and palate in this patient is unknown, from the



RSGM FKG UNPAD
RUMAH SAKIT GIGI DAN MULUT FAKULTAS KEDOKTERAN GIGI UMMER SITA E PADJADJARAN
Jl. Sekeloa Selatan I Bandung 40132 Telp. (022)2504885 Faks. (022)2532805 E-mail: fkg@unpad.ac.id

NOMOR REKAM MEDIS
NAMA

SURAT PERNYATAAN PERSETUJUAN TINDAKAN MEDIS

Isi kolom ini, bila pasien bisa membuat pernyataan sendiri
Isi kolom ini, bila pasien tidak bisa membuat pernyataan sendiri (tidak sadar, anak-anak, dibawah pengampuan)


Saya yang bertandatangan di bawah ini:
 Nama
 Alamat
 Umur tahun
 Jenis Kelamin:
 Saya yang bertandatangan di bawah ini:
 Nama
 Alamat
 Umur: 45 th tahun bulan
 Jenis Kelamin: Perempuan
 adalah ibu dari pasien RSGM FKG Unpad
 Nama
 Alamat
 Umur: 13 tahun bulan
 Jenis Kelamin: Laki - laki

dengan ini menyatakan bahwa saya telah menerima informasi lengkap tentang tindakan medik yang akan dilakukan, termasuk didalamnya efek samping dan resiko yang mungkin terjadi akibat tindakan medik tersebut, sebagaimana tertera secara tertulis pada bagian belakang surat pernyataan ini, oleh karena itu saya tidak akan mengajukan tuntutan apabila kemudian efek samping dan resiko itu terjadi.



Saya juga telah menerima informasi dan menyatakan setuju, bahwa karena RSGM FKG Unpad adalah rumah sakit pendidikan maka pelayanan medik yang diberikan dapat dilakukan oleh calon dokter gigi atau calon dokter gigi spesialis di bawah supervisi dokter gigi atau dokter gigi spesialis.

Coret pernyataan ini bila tidak digunakan:
 Untuk keperluan pendidikan saya juga menyatakan setuju untuk dibuatkan sebanyak 2 buah oleh 2 orang operator yang berbeda.

Demikian surat persetujuan ini dibuat tanpa ada paksaan dan tekanan dari pihak manapun, untuk dipergunakan sebagaimana mestinya.

Bandung, 22 - 2 - 2015
 Yang membuat pernyataan


Saksi-Saksi

(drg. Dyah Nidita C. Sp. Perio CK) 
 (drg. Chandra andi Basoro Sp. Perio 

Saksi: satu orang dari pihak pasien, satu orang dari pihak rumah sakit, atau bila tidak ada keduanya dari pihak rumah sakit

Figure 3: Informed consent that signed by the patient's mother.

anamnesis data obtained during pregnancy the mother never suffered from a serious illness, didn't smoke or consume teratogenic drugs. There is no family history of the cleft in mouth or face. Cleft lip and palate caused by the interaction of genetic and environments [12].

In this case, the patient had orthodontic treatment for almost a year. The patient was referred to Periodontic Departemen because of enlargement in maxillary anterior gingiva teeth and blocking the placement of braces. On the first visit, the patient's oral hygiene wasn't good. The presence of an orthodontic appliance, crowding, and

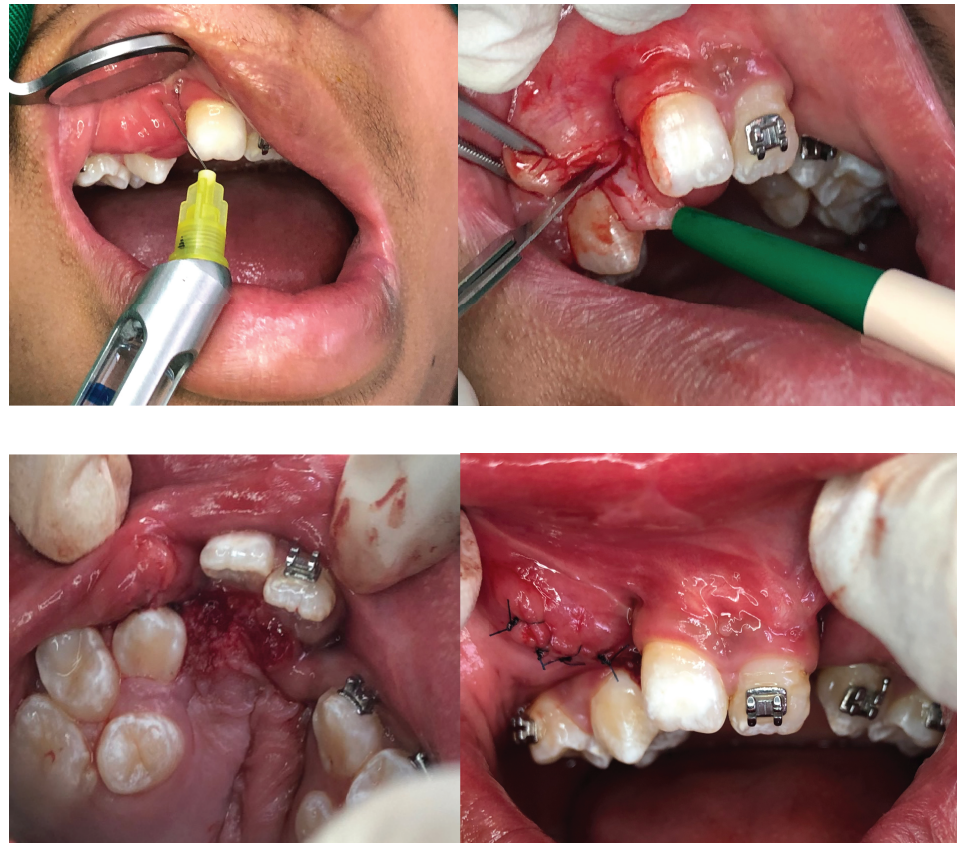

Figure 4: The procedure of gingivectomy.

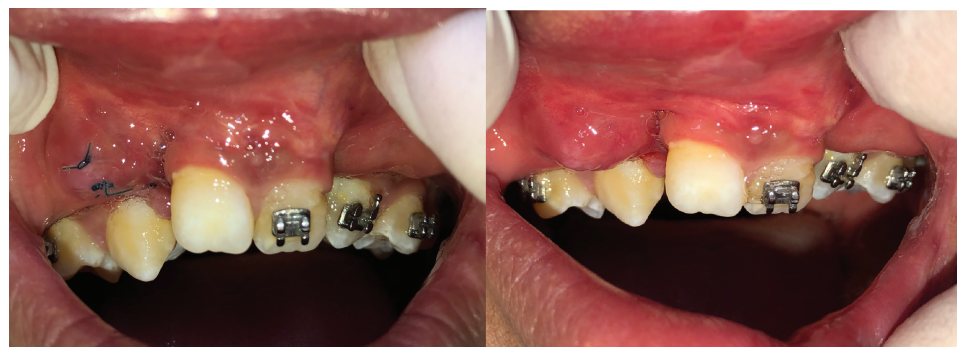

Figure 5: One week after surgery.

malformation of the teeth may hamper optimal oral hygiene. In this case, after being given oral hygiene instruction, the oral hygiene continued to improve. Maintaining good oral hygiene is an important key for patients with periodontal problems. Numerous periodontal problems unique to cleft lip and palate patients arise from extensive surgical, orthodontic, and prosthetics rehabilitation [5]. Furthermore, according to Bragger and co-workers, due to inadequate oral hygiene, adult patients with clefts demonstrated early signs of periodontitis with furcation involvement in most cases [6]. Diminishing

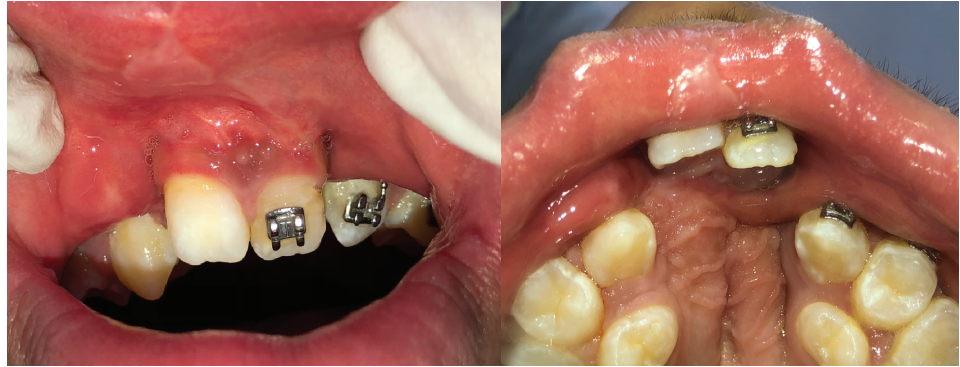


Figure 6: One month after surgery.

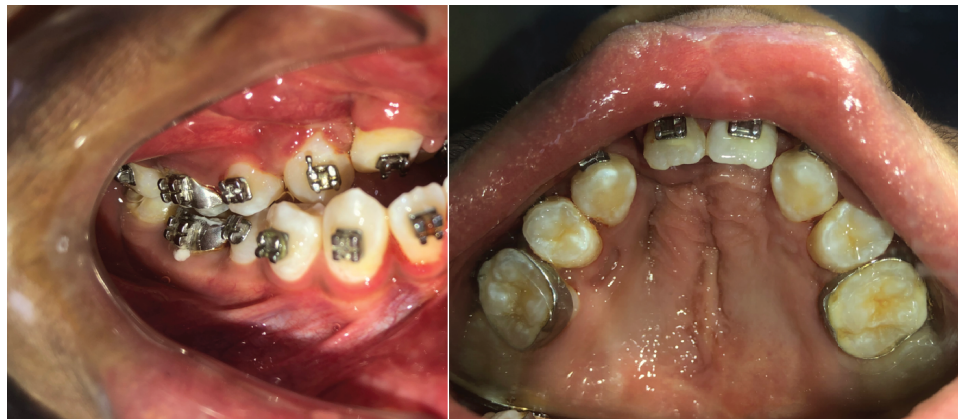

Figure 7: Three month after surgery.

plaque mass will reduce the injury on the periodontal tissues [13]. So that, the patient can maintain of healthy gingiva and provide better healing after surgery.

The etiology and pathogenesis of gingival enlargement, in this case, are still not well established, it could be directly linked to individual susceptibility, local factors (dental plaque, orthodontic appliances, and iatrogenic factors), and patient's pubertal ages.

The treatment methods for gingival enlargement are dependent on the severity of the lesion. When the enlargement is minimal, home care maintenance and scaling may be sufficient. When the enlargement is massive, surgical excision is required. Various techniques used for the excision of the enlarged lesion, include internal or external bevel gingivectomy, electrocautery, and carbon dioxide laser [14]. In this case, consider the severity of gingival enlargement, an internal bevel gingivectomy was done under local anesthesia. This surgical therapy succeed to reduce pockets, facilitate placement of orthodontic appliances, improve the esthetics and the access for plaques control. In the present case, the patient shows no evidence of recurrence during three months of follow up.

There are only a few studies on periodontal conditions in growing patients with clefts. Periodontal diseases were higher risk progressed in patients with clefts if no supportive periodontal therapy in their early childhood. The periodontology acts in combination with community health for oral hygiene instructions and control, during surgical, orthodontic, and rehabilitative treatment [15].

Cleft lip and/or palate patients require multidisciplinary care from birth to adulthood. A comprehensive treatment plan handling by an expert group of specialists can establish an optimal oral condition [2,3].

5. Conclusion

The cleft lip and/or palate patients require to be evaluated, treated, and critically analyzed by a multidisciplinary team. Periodontal treatment should begin early and continue as supportive therapy. Gingivectomy is effective to support orthodontic treatment for cleft lip and/or palate patients.

References

- [1] Chowchuen B, Godfrey K. Development of a network system for the care of patients with cleft lip and palate in Thailand. *Scandinavian Journal of Plastic and Reconstructive Surgery and Hand Surgery*. 2003;37(6):325-331. <https://doi.org/10.1080/02844310310005388>
- [2] Ahmed MK, Bui AH, Taioli E. Epidemiology of cleft lip and palate. Designing strategies for cleft lip and palate care. *IntechOpen*. 2017: 3-22. <http://dx.doi.org/10.5772/67165>
- [3] Villagra LN, Domon M, Méndez VS. Comprehensive orthodontic treatment of adult patient with cleft lip and palate. *Case Reports in Dentistry*. 2014. Volume 2014:1-4. <https://doi.org/10.1155/2014/795342>
- [4] Guerrero C. Cleft lip and palate surgery: 30 years follow-up. *Annals of Maxillofacial Surgery*. 2012;2(2):153-157. <https://doi.org/10.4103/2231-0746.101342>
- [5] Bloor V, Thomas B. Comparison of periodontal status among patients with cleft lip, cleft palate, and cleft lip along with a cleft in palate and alveolus. *Journal of Indian Society of Periodontology*. 2010;14(3):168-172. <https://doi.org/10.4103/0972-124x.75911>
- [6] Wyrębek B, Cudziło D, Plakwicz P. Evaluation of periodontal tissues in growing patients with bilateral cleft lip and palate. A pilot study. *Developmental Period Medicine*. 2017;21(2):154-161.

- [7] Perillo L, D'Apuzzo F, Eslami S, Jamilian A. Designing strategies for cleft lip and palate care. Almasari MA, editor. IntechOpen; UK. 2017. Cleft lip and palate patients diagnosis and treatment. <https://doi.org/10.1016/j.colsurfa.2011.12.014>
- [8] Mancini L, Gibson TL, Grayson BH, Shetye PR. Orthodontic treatment in adolescents with cleft lip and palate. *Seminars in Orthodontics*. 2017;23(3):295- 304. <https://doi.org/10.1053/j.sodo.2017.05.005>
- [9] de Souza Freitas, J.A., de Almeida, A.L.P.F., Soares, S., et al. Rehabilitative treatment of cleft lip and palate: Experience of the hospital for rehabilitation of craniofacial anomalies/USP (HRAC/USP) - Part 4: Oral rehabilitation. *Journal of Applied Oral Science*. 2013;21(3):284-292. <https://doi.org/10.1590/1679-775720130127>
- [10] Reddy S. *Essentials of and periodontics*. New Delhi: Jaypee Brothers Medical Publisher (P) Ltd; 2011.
- [11] Newman M, Takei H, Klokkevold PCF, Carranca FA. *Newman and Carranza's clinical periodontology*. 13th ed. Philadelphia: Elsevier; 2019.
- [12] Loose JE, Kirschner RE. *Comprehensive cleft care*. 2nd ed. New York: Thieme Medical Publisher; 2016.
- [13] Van Der Weijden F, Slot DE. Oral hygiene in the prevention of periodontal diseases: The evidence. *Periodontology 2000*. 2011;55(1):104-123. <https://doi.org/10.1111/j.1600-0757.2009.00337.x>
- [14] Nagarale GP, Ravindra S, Thakur S, Setty S. Long term follow up of idiopathic gingival enlargement associated with chronic periodontitis: A case report and review. *Journal of Indian Society of Periodontology*. 2013;17(2):242-247. <https://doi.org/10.4103/0972-124X.113088>