

Conference paper

Results of Subantral Augmentation with Application of Implants with Permeable Porosity

I.D. Tazin^{1,2*}, D.I. Tazin², M.N. Shakirov²

*Corresponding author:

I.D. Tazin, email:

If_ssmu@mail.ru

¹Research Institute of Medical Materials and Implants with Shape Memory, Tomsk, Russia

²Siberian State Medical University, Tomsk, Russia

Received: 23 March 2017

Accepted: 9 April 2017

Published: 16 July 2017

**Publishing services
provided by Knowledge E**

Copyright © 2017 I.D. Tazin et al. This article is distributed under the terms of the [Creative Commons Attribution License](#), which permits unrestricted use and redistribution provided that the original author and source are credited.

Selection and Peer-review under the responsibility of the SMBIM Conference Committee.

Abstract

The method of open antral augmentation with the application of dental implants with permeable porosity in a high grade atrophy of the maxilla alveolar process is rather promising and effective. It results in considerable improvement of orthopedic treatment of patients with tooth line defects. A considerable contact area of the porous permeable dental implant with the bone makes it possible to use 9-11 mm-long implants for prosthetics in the maxilla lateral region.

1 Introduction

At present there are many techniques improving dental implantation. One of the most common techniques making dental implantation in the maxilla lateral region easier is subantral augmentation which is oftener called «sinus lifting». Accurately planned and competently performed the operation of subantral augmentation permits successful insertion of reliable implants capable to stand great biomechanical overload arising during mastication [1, 2, 3].

The aim of the study was to evaluate the remote results of application of Nickelide Titanium porous permeable dental implants in operations of open subantral augmentation.

 OPEN ACCESS

2 Materials and methods

The operation of sinus lifting has been performed in the Clinic of dental implantology in Tomsk since 1994. Over this period the results of maxilla surgical reconstruction with lifting of the maxilla sinus base have been analyzed in 188 patients. The patients' age was 27-65 years.

There were 104 female and 84 male patients. Preoperatively a complex examination was carried out. It included clinical assessment, X-ray examination, endoscopic (if indicated) evaluation of the maxilla sinus, examination of the jaw models, oral cavity and ENT-organs sanitation. A considerable atrophy of the alveolar process in the maxilla distal region was revealed in all patients. Thickness of the osseous base in the maxilla sinus area was not more than 5 mm which significantly complicated insertion of the intraosseous dental implants (Fig. 1).

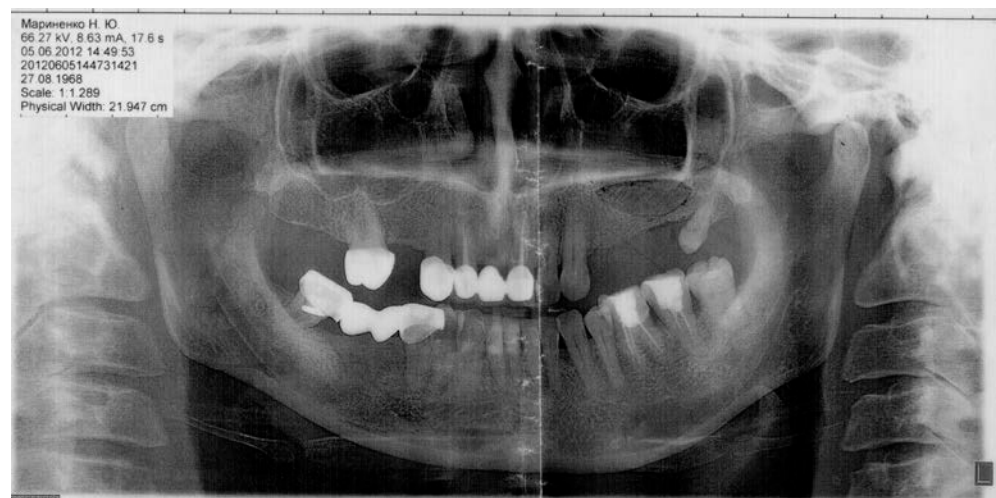


Fig. 1. The X-ray of the patient before the surgical treatment

During sinus lifting procedure dental implants were inserted to 165 patients, the rest underwent this procedure later. In our work we applied dental implants with a through porosity, the size of pores being 0.1-0.3 mm with the diameter of 3.3- 4.0 mm and 9-12 mm long. Both Russian and foreign materials and autotransplants were used as osteoplastic material. The operations were performed under ambulatory conditions, with premedication, under conduction and infiltration anesthesia with amid- type anesthetics. Depending on the operation volume antibiotics, desensitizing reparations and pain-killers were administered in the

postoperative period. The operation was performed according to Tatum method with distal-lateral approach of our modification (Fig. 2).

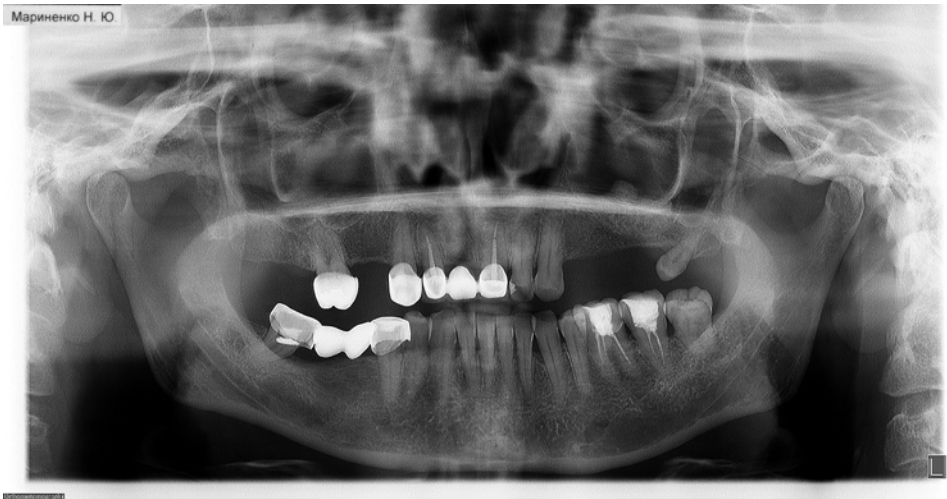

Fig. 2. The X-ray of the same patient 6 months after the surgical treatment

3 Results of the study

After the operation of sinus lifting with application of TiNi porous permeable dental implants 180 patients had no complaints in respect of maxilla sinus and implants. The implants were stable and osteointegrated. X-ray examination revealed no pathological reabsorption of the osseous tissue around the implant neck (Fig. 3).

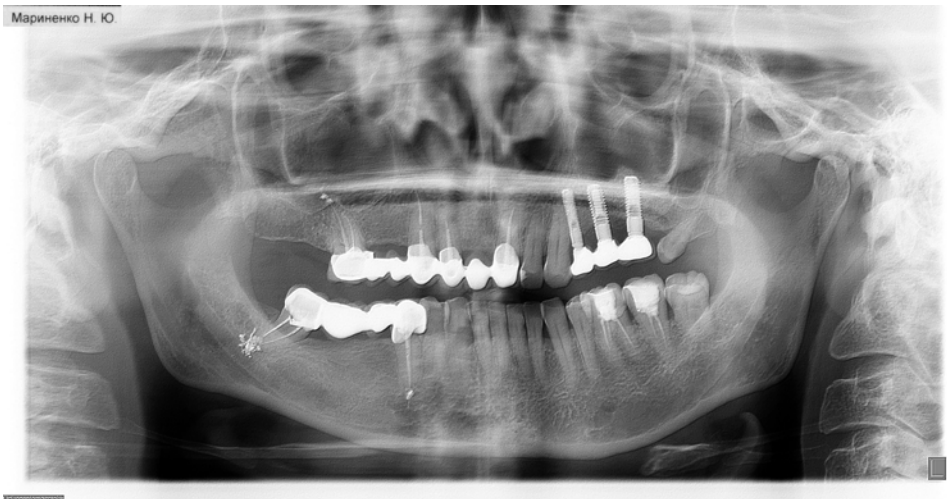

Fig. 3. The X-ray of the same patient 4 years after the prosthetics
 A vertical growth of the osseous tissue was observed. The sinuses were of normal

transparency. Remote postoperative endoscopic examination did not reveal any signs of the maxilla mucous membrane inflammation. The 18-year follow-up showed that good functional and esthetic results were obtained in prosthetics on dental implants in 96.2% of cases.

4 Conclusion

Thus, the method of open antral augmentation with the application of dental implants with permeable porosity in a high grade atrophy of the maxilla alveolar process is rather promising and effective. It results in considerable improvement of orthopedic treatment of patients with tooth line defects. A considerable contact area of the porous permeable dental implant with the bone makes it possible to use 9-11 mm-long implants for prosthetics in the maxilla lateral region.

5 Acknowledgments

TiNi-based medical materials and implants (porous permeable dental implants) were developed and manufactured at the Research Institute of Medical Materials and Implants with shape memory (Tomsk).

References

- [1] R. Haas, Avoiding sinus graft surgery, *Clinical Oral Implants Research*. 21 (2010) 995.
- [2] R.M. Pillar, G. Sagals, S.A. Meguid et al., Threaded versus porous-surfaced implants as anchorage units for orthodontic treatment: three-dimensional finite element analysis of peri-implant bone tissue stresses, *Int. J. Oral Maxillofac. Implants*. 21 (2006) 879-889.
- [3] M. Simion, Stage lateral augmentation for implant surgery, *Clinical Oral Implants Research*. 21 (2010) 996.