

Conference paper

Operative Treatment Unoperative Chronic and Massive Rotator Cuff Tendon Rupture of the Shoulder

Lanshakov V.A.¹¹NSIFTPH – Branch Campus of the FSBEI FPE RMACPE MOH Russia (Novokuznetsk, Russia)

*Corresponding author:
V.A. Lanshakov email:
asunta830@gmail.com

Received: 23 March 2017

Accepted: 9 April 2017

Published: 16 July 2017

Publishing services
provided by Knowledge E

Copyright © 2017 V.A.
Lanshakov. This article is
distributed under the
terms of the [Creative
Commons Attribution
License](#), which permits
unrestricted use and
redistribution provided
that the original author and
source are credited.

Selection and Peer-review
under the responsibility of
the SMBIM Conference
Committee.

OPEN ACCESS

Abstract

In clinic of traumatology and orthopedics GBOU DPO NGIUV was treated 125 patients with tendon rupture rotators of the shoulder joint, in which treatment was used as the classic methods of surgical treatment, and we have developed approaches and methods of surgical treatment with the use of sutures and staples of nickelid titanium allowing to bring the number of positive outcomes to 84.8%.

1 Introduction

In chronic massive (III degree) injuries treated ruptures of the rotator cuff tendons, in most cases, is intractable problem. Accentuation unoperative form gaps (massive irreparable rotator cuff tear) by foreign podiatrists, developing joint instability and rotator arthropathy (rotator cuff - tear arthropathy) is justified, and surgical treatment of severe injury is possible by using, for arthroplasty, tendons surrounding muscles (subscapularis, pectoralis major, latissimus, teres minor, deltoid), both alone and in combination, to stabilize the shoulder head tenotomy and tenodesis of the long head of the biceps, tuberoplasty and as a reserve - prosthetic shoulder joint [3, 4, 5]. In the available domestic literature we could not find information about the surgical treatment of severe damage to the rotator cuff. Our experience in the treatment of these lesions, especially with the use of implants of the nickelid titanium, is especially interesting for domestic orthopaedic traumatologists.

2 Materials and Methods

Among 125 patients admitted with tendon ruptures (except the long head of the biceps) rotators of the shoulder joint were 89 male (71.2%), 36 female (28.8%) compared with the corresponding $P < 0.05$). And significantly more damage to the rotator tendons of the shoulder were observed in older age groups (over 50 years) than younger (40 years) when compared $t = 5,85$; $P < 0.001$, which confirms the literature data on the effect of the age factor (early amortization braditrofnyh tissue) in the genesis of damage tendons shoulder rotators and persons of working age (increased requirements to the tissues of the shoulder joint at work). Reduced tissue elasticity, vascularization deterioration with age calcification and many other factors play an important role in the extent of the lesions. For example, massive (II-III degree of damage) gaps revealed in 91 (72.8%) patients older than 50 years ($P < 0.01$) more frequently than 1 degree of damage. The average age of male 55.8 years (31-72 years), female 56.7 (35-68 years), the dominant arm was injured in the majority of cases (75% of men). The timing (after traumatic injury to surgery) patients were: up to 4 weeks - 8 (6.4%), from 1-3 months - 58 (46.4%), 3-6 months - 48 (38.4%) and more than six months after trauma - 11 (8.8%) patients (average 122 days).

Late submission of the appeals (in 83.3% of cases) for surgical treatment due to a difficult diagnosis of damage to a wide variety of practitioners, and lack of knowledge of the pathology of the rotator cuff.

We done 33 of the 91 patients with old fractures and massive rotator tendons of the shoulder (third degree) and we used transosseous (and oblique V-shaped extended) approaches followed osteosynthesis brackets of nickelid titanium [1, 2] developed by us. Accesses to the shoulder joint were performed with simultaneous decompression of the subacromial space. For reinsertion tendons in half of patients with suture we used material made of Codman's nickelid titanium-transosseous fixation and extramedullary fixation brackets of nickelid titanium.

Five (33.3%) patients with chronic injuries, in order to avoid the eruption of joints, improve revascularization, increasing the durability of transossal fixation we used reinsertion method we have developed by RF patent number 2202972 pr. From 13.06.2001.

This technical result is achieved by the fact that in the method of surgical treatment of tendon ruptures of the shoulder rotator muscles, which includes the formation of tendon package and the bone bed for him at the head of the humerus, accommodation and transosseous fixing tendons pack in the formed

bone bed, the packet shaping is carried out reinforcement of its volume plate implant porous nickelid titanium and cross-stitching and implant tendons package and secure it in the bone bed suture from a superelastic nickelid titanium. Housed in a thicker tendons packet porous plate implant is armature, that strength and forming frame of this composition. Its presence increases the mechanical durability of the package, therefore, the durability of the attachment of muscles to the bone - the main quality of the operation. The porous material of nickelid titanium overgrown by flesh, vascularized and complements the blood supply to the entire package. High mechanical durability of the generated package allows to minimize its dive and bone bed itself, that is emergency trauma humerus. This helps to reduce patient recovery periods.

Clinical example. Patient M., 54 years old. In 2008 he enrolled the hospital trauma department with a long-standing injury the tendons of the right shoulder external rotators IV degree, syndrome shoulder-brush mild degree. He fell 2 months before admission, was treated in a fracture clinic about the lower shoulder dislocation. Then treatment is complicated by the formation of post-traumatic syndrome, shoulder-brush. The patient does not feel the effect of the treatment. Then was made the operation, by the method of surgical treatment (RF patent N^o2202972, pr. 2001). The patient was examined spend 4 months after surgery, a full range of motion, good results (Fig. 1).

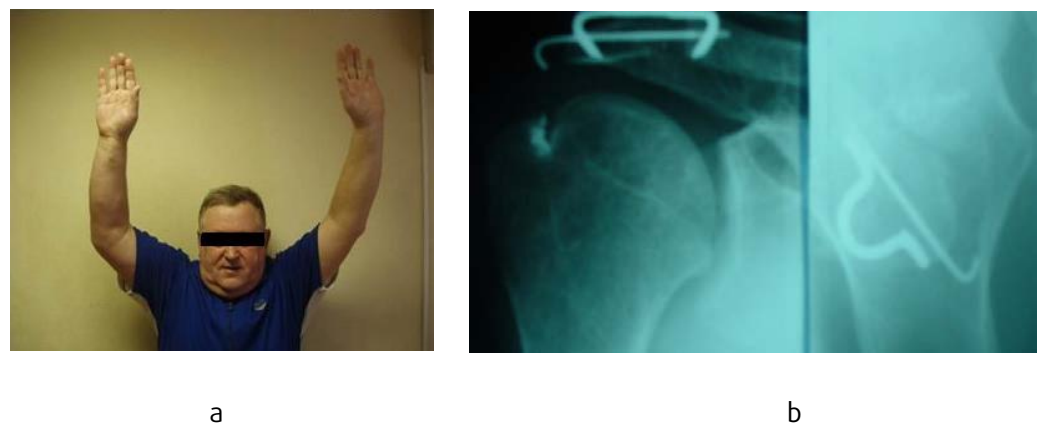

Fig. 1. Patient M., 54 years old, radiographs (after surgery) with a long-standing tendon rupture unoperative external rotators of the right shoulder. a - reinsertion made by RF patent N^o2202972; b - photo of the patient 4 months after surgery. The amount of motion in the shoulder joint is full, a good treatment result

Five patients formed packs roaming the subscapularis tendon and infraspinatus muscle in 3 - subscapularis and teres minor muscle according to the method of surgical treatment (Patent N^o2429793, pr. from 17.03.2010.) Using mesh implants from nickelid titanium and extramedullary fixation brackets of nickelid titanium.

Clinical example. Patient B., 52 years old, entered the clinic of traumatology and orthopedics in Novokuznetsk GIUVa in 2007 with a long-standing gap unoperative rotator tendons of the right shoulder III century. Operation proposed method of surgical treatment by RF patent N°2429793 - (Fig. 2).

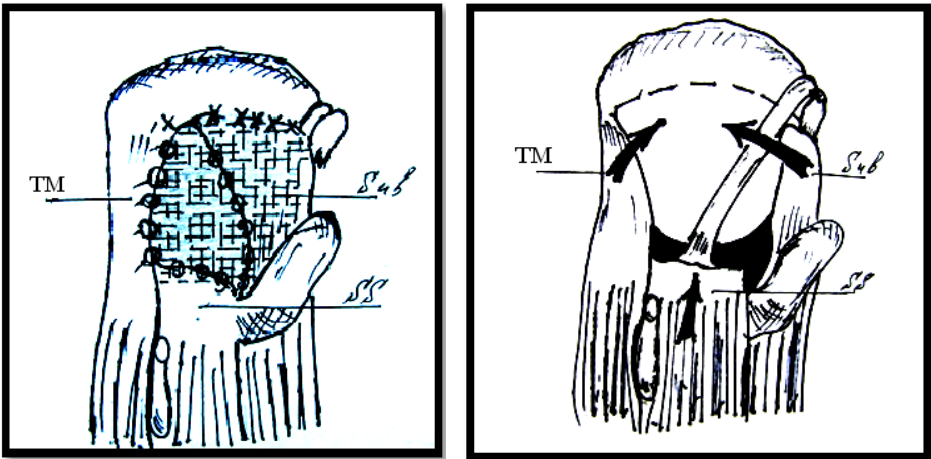


Fig. 2. Scheme tendons autoplasty proposed method of surgical treatment (RF patent N° 2429793) using the mesh implant of TiNi

Examination after two years. Patient has no complaints, the movement of the shoulder joint in full, joint stable, humeral articular surface is congruent. The result of surgical treatment - excellent. On radiographs of the shoulder joint is determined by the mesh implant in the subacromial bag (Fig. 3). The other patients received stabilization of the humeral head using tenodesis and tenotomy of the long head of the biceps transosseous and extramedullary fixation brackets of the nickelid titanium and application of mesh implants.

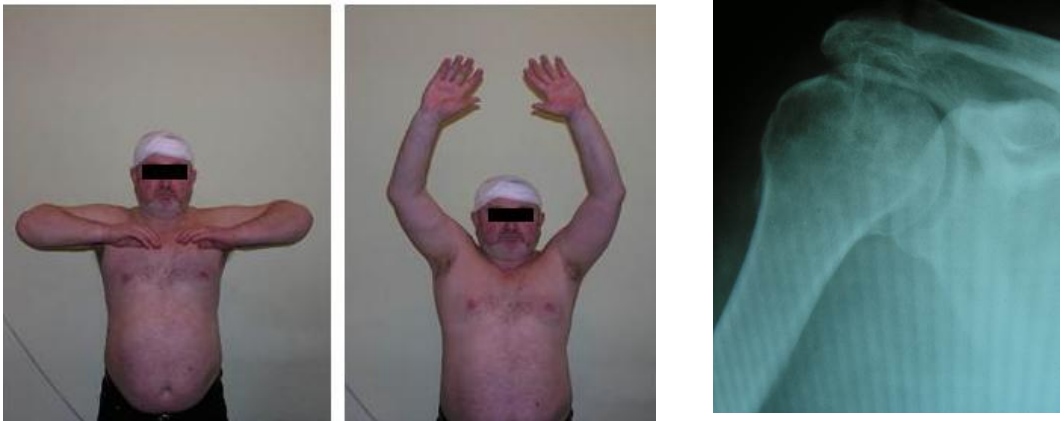


Fig. 3. Radiographs of the shoulder joint and the patient B. 52 years old, two years after surgery. Arrow indicated mesh implant of the nickelid titanium in the subacromial joint, treat result is excellent.

Clinical example. Patient P., 51 years old, enrolled at clinic of traumatology and orthopedics with unoperative tendon ruptures of the rotator cuff. Was carried stabilizing operation with the use of the mesh implant, tenotomy and tenodesis tendon of the long head of these biceps with extramedullary fixation bracket of nickelid titanium. He was examined after one year (Figure 4), a good result.

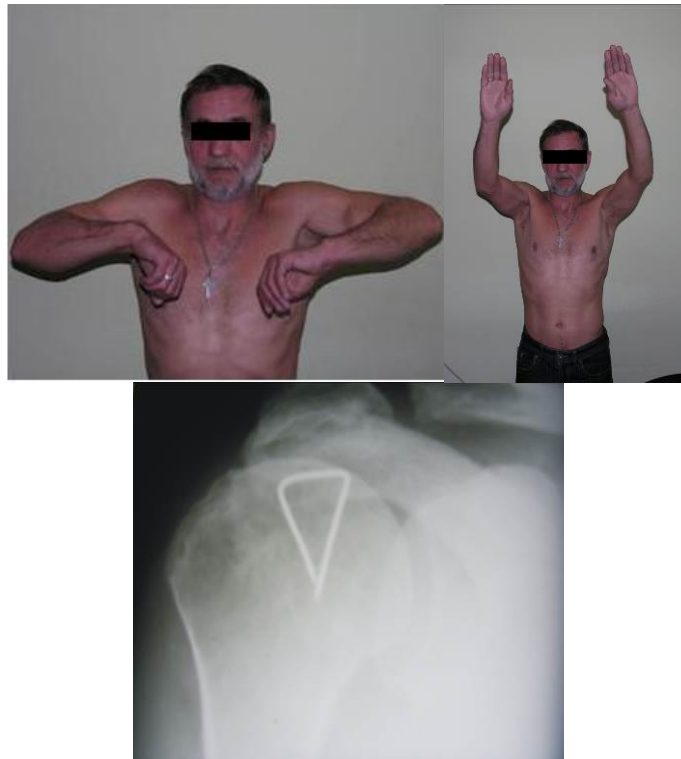

Fig. 4. Patient P., 51 years after 1 year after the operation, the amount of movement in the joint is full, a good result. At the head of the humerus (radiographically determined bracket of nickelid titanium)

Results and discussion. Late results of surgical treatment were studied for patients with all forms unoperative tendon ruptures shoulder rotators by L.U. Bigliani. (1992) and found good and satisfactory results in the majority of victims - 28 (84.8%), bad - in 5 (15.2%) patients. There was a significant difference of the results of treatment by age, time since injury, the severity of traumatic injuries.

The success of the surgical treatment of injuries consists in the further improve diagnostic methods, developing strict indications for the use of differentiated (that is planning) of operative treatment depending on the pathogenetic situation, underlying the existing damage tendons of the rotator cuff. And ways to improve the surgical treatment possible when using mesh implants made of nickelid titanium wire thru-bone seam and plate osteosynthesis and transosseous

application accesses the shoulder joint.

Acknowledgments

TiNi-based medical materials and implants (porous plates, mesh and solid brackets) were developed and manufactured at the Research Institute of Medical Materials and Implants with shape memory (Tomsk).

References

- [1] V.A. Lanshakov, V.E. Gunther et.al., *Medical Materials and Implants with Shape Memory, The implants with shape memory in traumatology and orthopedics* [in Russian]. MIC, Tomsk, 2010.
- [2] V.A. Lanshakov, *Transosseous accesses the shoulder joint in diseases and lesions (anatomic substantiation), Implants with Shape Memory* [in Russian], MIC, 1 (1993) 6-9.
- [3] E.A. Codman, *The shoulder, Rupture of the supraspinatus tendon and other lesions in or about the subacromial bursa*, Thomas Todd Company, Boton, 1934.
- [4] R.H. Cofield, *Subscapsular musche transposition for repair of chronic rotator cuff tears*, *Surg. Gynecol. Obstet.* 154 (1982) 667-672.
- [5] P. Paavolainen, *Teres minor transfes, Jn: Burkhed Wzjn.*, ed *Rotator cuff Disorders*, Baltimore, MD.