

## Conference Paper

# Ellagic Acid Activity in Healing Process of Incision Wound on Male Albino Rats (*Rattus norvegicus*)

Hardany Primarizky, Wiwik Misaco Yuniarti, and Bambang Sektiari Lukiswanto

Department of Veterinary Clinic, Faculty of Veterinary Medicine, Universitas Airlangga Campus "C", Mulyorejo, 60115, Surabaya, East Java, Indonesia

## Abstract

This study was conducted to prove whether ellagic acid can be used as a regulator of incision wound healing process in male albino rats as experimental animals. A total of 24 male healthy rats based on physical examination, aged at 3 months old and weight at 150-180 grams used in this study. Rats were divided into three groups and each group has 8 replications, group of control (Po) has no incision wound and no medication, treatment group (P1) has incision wound and treated with Betadine® and (P2) has incision wound and treated with 2,5 % ellagic acid. The variable that observed are histopathology changes (collagen, PMN, angiogenesis and fibrosis) from the male albino rats. The samples collection was taken at day 15 and data were collected and analyzed by Analysis of Variance (ANOVA) test. The result of collagen and PMN cells score in the control group (Po) were  $1.80 \pm 0.16$  and  $1.6 \pm 0.08$  with mild angiogenesis and no fibrosis. The results in the treatment (P2) group, where the collagen and PMN scores were  $1.60 \pm 0.08$  and  $1.5 \pm 0.8$ , accompanied by mild angiogenesis and fibrosis. Meanwhile, in the treatment (P1) group, the results of scoring of collagen and PMN were lower than the other groups,  $0.80 \pm 0.08$  and  $0.6 \pm 0.16$  accompanied by moderate angiogenesis and fibrosis. There was a significant difference of collagen scoring, PMN cells number, fibrosis and angiogenesis among the treatment groups ( $p < 0.05$ ). P1 treatment group has significant different with treatment groups Po and P2 ( $p < 0.05$ ), but there is no significant difference between treatment groups Po and P2 ( $p > 0.05$ ). From the results, it can be concluded that the topical application of ellagic acid ointment was proved to provide healing process on incision wound. Topical administration of ellagic acid ointment for 14 days was able to improve the skin condition and promoted the wound healing.

**Keywords:** Ellagic acid; wound healing; collagen; angiogenesis; fibrosis; anti-inflammatory; antioxidant; antibacterial.

Corresponding Author:

Hardany Primarizky  
hardany-p@fkh.unair.ac.id

Received: 03 October 2017

Accepted: 10 October 2017

Published: 29 November 2017

Publishing services provided  
by Knowledge E

© Hardany Primarizky  
et al. This article is distributed  
under the terms of the

Creative Commons Attribution  
License, which permits  
unrestricted use and  
redistribution provided that  
the original author and source  
are credited.

Selection and Peer-review  
under the responsibility of the  
VMIC Conference Committee.

## OPEN ACCESS

## 1. Introduction

Wound is a condition of tissue damaged continuity caused by trauma from sharp or dull objects, temperature changes, chemical materials, electricity, radiation or animal bites. An incision wound is a wound on the skin surface that frequently caused by contact with a sharp object [1-4].

Wound healing is a process of the body to repair the tissue damaged to be functioned again. The body tried to regulate the abnormal conditions as a result of healing process. The body responded if the skin integrity was damaged and presented an overlapped phase but biologically distinguishable. After wound occurred, the healing phase that involved are inflammation, proliferation and remodeling [18].

The wound healing process can be disrupted by the causes from the body itself (endogenous) and from external causes (exogenous). The most important endogenous causes are impaired coagulation and immune system disorder. Both of these conditions will inhibit wound healing with changes of body reactions to injury, necrosis and contamination. Exogenous causes that can affected wound healing process include radiance ionization, cytostatic agents' administration and immune suppressant drug like corticosteroid [6].

Nowadays the patent medicines are served to optimized wound healing process like burn wounds, incision wounds or any other wounds. The available drugs has many disadvantages such as expensive price and not affordable for everyone. Furthermore, the consideration of synthetic chemical substances addition have some side-effects that influenced other vital organs. That consideration made some researcher did studies about natural herbs as an alternative for medical treatments [7].

One of the most widely studied medicinal plants for health problems is pomegranate or *Punica granatum* Linn (PGL). The antioxidant and anti-inflammatory activity from Pomegranate are due to the very high content of polyphenols. Polyphenols that contained in pomegranates are ellagic acid (EA), gallotannins, anthocyanins and others [8].

Ellagic acid is the active ingredient that widely studied and it's a polyphenol that has much activities as an antioxidant, anti-inflammatory and as a regulator on fibrosis process with decreasing the excess collagen level on the chronic lesion tissues [9, 10].

This study was conducted to prove whether ellagic acid can be used as a regulator of incision wound healing process in male albino rats as experimental animals.

## 2. Materials and Methods

## 2.1. Materials

The materials that used in this study were 90% ellagic acid produced by Xi'an Biof. Bio-Technology Co., Ltd., Ketamine® and Diazepam for anesthesia, sterile aquadest, vaselin flavum, Betadine®, 70% ethanol, pellet feed, 10% buffered formalin for organ fixation to avoid damage, Entellan® for mounting cover glass, absolute alcohol solution for dehydration stage (96%, 80%, 70%), xylol for clearing phase, and HE staining for the histopathological staining.

The tools for this study were ACIS® digital scales for weighing albino rats, surgical equipment for making an incision wound are gloves, scissors, sterile cotton, plastic spoon, cotton bud, tissue forceps, artery forceps, sterile gauze, scalpel no.3, blade no.10 and tissue container. The tools for making ointment such as stamper and mortar also needed, then the tools for histopathological slide such as microtome, embedding set, slides, cover slides, staining set and microscope for observation and camera.

## 2.2. Methods

This study used male albino rat (*Rattus norvegicus*) as an experimental animal. A total of 24 male with rats were healthy based on physical examination, aged at 3 months old and weight at 150-180 grams used in this study. 24 male albino rats (*Rattus norvegicus*) as an experimental animal with one week adaptation for preparing and checking the health status. After a week of adaptation, the rats divided into three groups and each group has 8 replications. The variable that observed are histopathology changes (collagen, PMN, angiogenesis and fibrosis) from the male albino rats. Control group animals (Po) has no incision wound and no medication. Treatment groups (P1) has incision wound and treated with Betadine® and (P2) has incision wound and treated with 2,5% ellagic acid. Animals then were euthanized and skin samples on day 15 were harvested.

After 1 week of adaptation, the albino rats were shaved on their dorsal body of 3 cm x 2,5 cm to facilitate the incision process. For that procedure, anaesthetic agents were administered with combination of Ketamin® and Diazepam (100mg/ml : 5 mg/ml) at dose level of 1 ml/kg body weight [11]. The incision wound made along 3 cm, 0,25 cm depth and 0,01 cm width in shaved skin region. The skin fixation was made and scalpel blade placed on skin surface with 30-40 angle then incision done with moved the scalpel blade caudally [12]. Treatment was done by applying Betadine® and Ellagic acid ointment with cotton bud, three times daily with 8 hours interval for 14 days [13]. Skin tissue sampling was done at day 15 with euthanasia procedure using Ketamin®.

TABLE 1: The comparison of healing process in each treatment groups based on collagen and PMN scores.

Treatment Groups	Collagen	PMN Cells
P <sub>0</sub>	1,80±0.16 <sup>a</sup>	1,6±0.08 <sup>a</sup>
P <sub>1</sub>	0,80±0.08 <sup>b</sup>	0,6±0.16 <sup>b</sup>
P <sub>2</sub>	1,60±0.08 <sup>a</sup>	1,5±0.8 <sup>a</sup>

Note: different superscript (<sup>a,b</sup>) indicate significant difference (p < 0.05). P<sub>0</sub>: control group; P<sub>1</sub> and P<sub>2</sub>: treatment group.

Skin tissue samples was taken at 0,5 cm depth and 1 cm extra on four sides for better sample quality [6].

The observation of histopathological slides was done with scoring technique that are defined as: Collagen: normal bundle: 2, unorganized / oedema: 1, amorphous: 0; PMN: 0-10: 2, 11-40: 1, > 40: 0; angiogenesis in 3 degrees ie. mild, moderate and severe; presence of fibrosis by measuring the collagen bundles thickness in 3 degrees ie. mild, moderate and severe [14].

All of data results from histopathology changes of collagen and PMN cells are taken at day 15 and analyzed with Kruskal-Wallis test continued with Mann-Whitney U test. The result of collagen and PMN cells numbers in the slides were calculated for individual groups also with the presence of angiogenesis and fibrosis.

### 3. Result

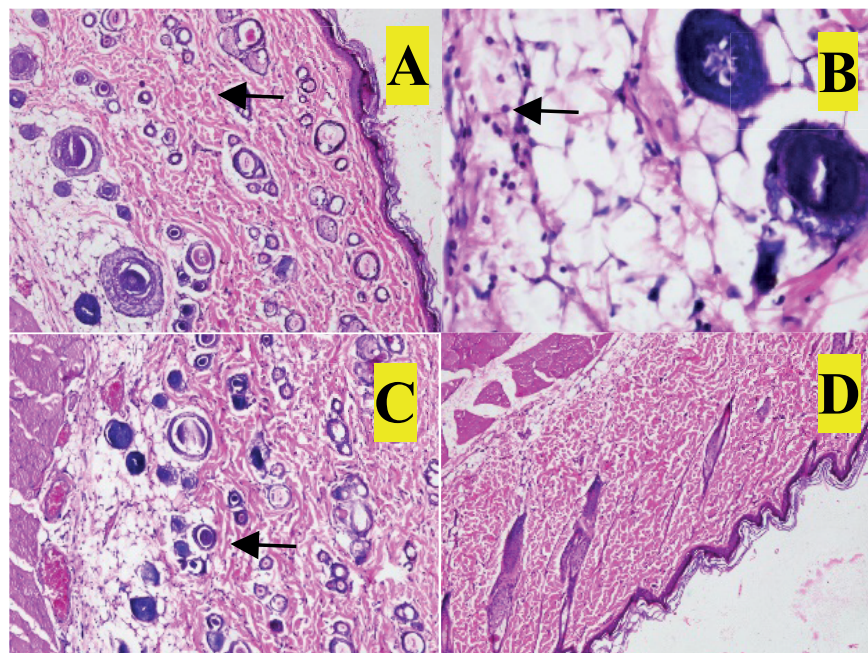
The statistical analysis result showed that ellagic acid gave an effect on healing process of an incision wound on albino rats as an experimental animals. This study also showed that there is a significant difference of collagen scoring, PMN cells number, fibrosis and angiogenesis among the treatment groups (p<0.05). P<sub>1</sub> treatment group has significant different with treatment groups P<sub>0</sub> and P<sub>2</sub> (p<0.05), but there is no significant difference between treatment groups P<sub>0</sub> and P<sub>2</sub> (p>0.05).

In the P<sub>0</sub> group, where the skin of mice was in good health, the collagen and PMN cells scores were 1.80 ± 0.16 and 1.6 ± 0.08 with mild angiogenesis and no fibrosis. The results were observed in the P<sub>2</sub> group, where the collagen and PMN scores were 1.60 ± 0.08 and 1.5 ± 0.8, accompanied by mild angiogenesis and fibrosis. Meanwhile, in the P<sub>1</sub> group, the results of scoring of collagen and PMN were lower than the other groups, 0, 80 ± 0.08 and 0.6 ± 0.16 accompanied by moderate angiogenesis and fibrosis. The comparison collagen and PMN scores on Table 1.

Based on data observed, the presence of angiogenesis and fibrosis are also obtained histopathological slide, as shown in Table 2.

TABLE 2: The presence of angiogenesis and fibrosis in each groups.

Treatment Groups	Angiogenesis	Fibrosis
P <sub>0</sub>	Mild	None
P <sub>1</sub>	Moderate	Moderate
P <sub>2</sub>	Mild	Mild

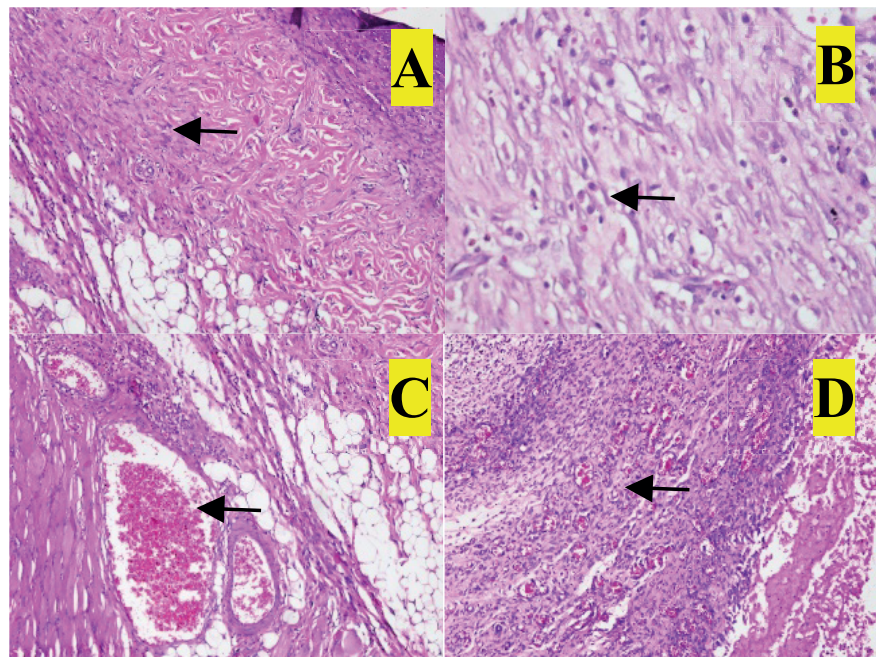


**Figure 1:** Histopathological cross section (shown by black arrow) of a skin with no incision wound and no treatment (P<sub>0</sub> control group). (A) Collagen score, (B) PMN score and (C) presence of mild angiogenesis and (D) absence of fibrosis. .

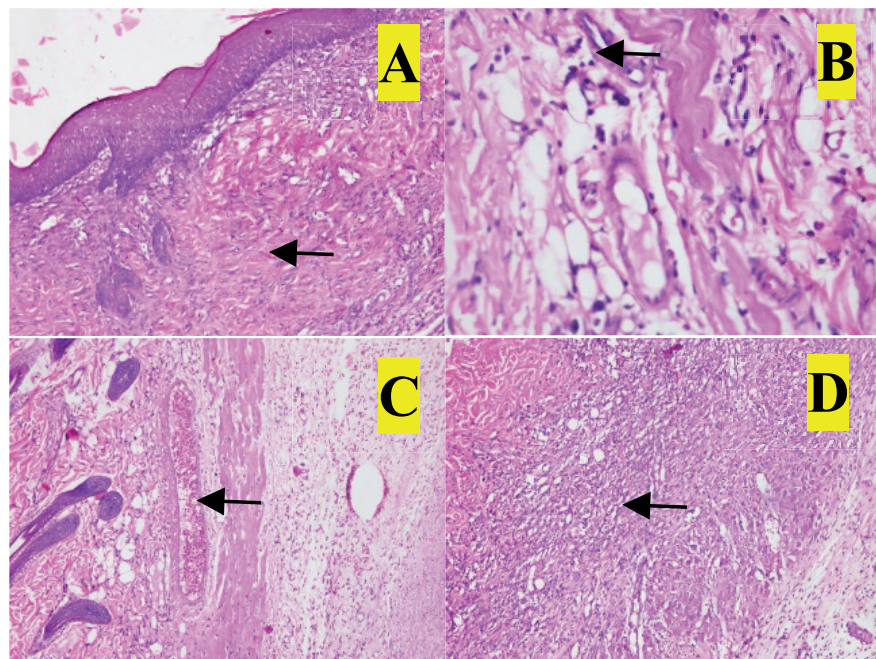
From the results, it seem that the topical application of ellagic acid ointment was proved to provide healing process on incision wound. Topical administration of ellagic acid ointment for 14 days was able to heal the skin consistently healthy.

#### 4. Discussion

The process of wound healing is a series of characterized condition that performed by combinations of biological processes that occurred in certain conditions and time. This process is marked by the restructuring of the damaged tissues to original condition. The natural response that occurred in healing process was repaired quite fast, and ensured the damaged tissues has completely returned to normal conditions [15].



**Figure 2:** Histopathological cross section (shown by black arrow) of a skin with incision wound and used Betadine® treatment (P1 group). (A) Collagen score, (B) PMN score and (C) presence of moderate angiogenesis and (D) presence of moderate fibrosis.



**Figure 3:** Histopathological cross section of a skin (shown by black arrow) of 15 days treatment with incision wound and used 2,5% of ellagic acid cream treatment (P2 group). (A) Collagen score, (B) PMN score and (C) presence of mild angiogenesis and (D) presence of mild fibrosis.

In this study, the group treated with topical ellagic acid ointment (P2), showed a better wound healing process when compared to the P1 group. There are several reasons that may cause the condition.

Ellagic acid, is a part of flavonoids which usually produced by various plants in tannin formation that known as ellagitannin. Ellagic acid two groups of lactons and 4 hydroxyl groups, where the hydroxyl groups have antioxidant activities so it prevent the lipid peroxidase and protect the tissue damages from oxidative stress. At this time, ellagic acid gets more attention because it has been shown to have antioxidant activity, chemo preventive and antiapoptosis, antimutagenetic, anti-inflammatory, anti-atherosclerosis, antifibrosis, antibacterial and anti-HIV replication [16].

Oxidative stress is one of the factors that inhibits wound healing process. Research on topical administration of natural ingredients that have antioxidant activity proved to improve the process of wound healing and prevent tissue damage due to oxidative stress [17, 18].

Inflammation is a protective process that happened to eliminated foreign materials then initiated the healing process. However, the excessive or imbalanced inflammatory process can delay the wound healing. Therefore, intervention was necessary to prevent the delayed of wound healing with administered of anti-inflammatory agents [19].

Infection can delay the process of wound healing by various mechanisms, such as lowering the blood supply, causing dysfunction of the leucocyte function, prolonging inflammatory and debridement processes and producing proteolytic enzymes. Therefore, infection is a complication of various types of wounds and antibiotics have an important role in wound healing processes [20–22].

Herbs contain tannins or ellagic acid in the form of ellagitannin has a therapeutic effect if used on wounds, either burns or other types of wounds. This is because of antioxidant activities, anti-bacterial and anti-inflammatory activities [23]. Ellagitannin or ellagic acid can help the precipitation of proteins in damaged tissues, so it can provide the scabs formation rapidly. This activity will also reduce the edema and exudative fluids on wound surface through decreasing of capillaries permeability [20, 24]. Beside that activity, other activities are thought to play a role in wound healing process from its ability as an angiogenic agent [25].

Based on the results of the research, to get the results of a good wound healing process, 2.5% of ellagic acid ointment should be given at the beginning of the initial phase of injury.

## 5. Conclusion

This study concluded that the application of 2,5% ellagic acid has an activity to promote healing process on incision wound. Therefore, to show the best result it suggested to use it frequently for 14 days.

## Acknowledgements

The authors are thankful to Faculty of Pharmacy and Faculty of Veterinary Medicine Universitas Airlangga, Surabaya for providing all the type of facilities to carry out this research. This research was funded by Faculty of Veterinary Medicine Universitas Airlangga with RKAT (Institutional Annual Fund) year 2017.

## References

- [1] M. Keane and M.T. O'Toole, Miller-Keane Encyclopedia & Dictionary of Medicine, Nursing & Allied Health, Revised Reprint, 7th Edition, Saunders. Elsevier (2005) 424.
- [2] H. Mifflin, The American Heritage Medical Dictionary, United States, Houghton Mifflin Company. 587, 2007.
- [3] B. D. Nagori and R. Solanki, Role of Medicinal Plants in Wound Healing. Research Journal of Medicinal Plant. 4.1 (2011) 392-405.
- [4] Reksoprodjo, Collection of Surgery Lectures. Faculty of Medicine, University of Indonesia, Jakarta, 2012.
- [5] M.D. Mc Gavin and J.F. Zachary, Pathologic Basic of Veterinary Disease. 5<sup>th</sup> Ed., St. Louis. USA. 2007.
- [6] P. Mathilda, Influence of Infuse Pare Fruit (*Momordica charantia* L.) Towards Incision Wound Healing Process in White Rat (*Rattus norvegicus*), Thesis. Faculty of Veterinary Medicine, Universitas Airlangga, Surabaya, 2000.
- [7] P.A. Wibawati, Influence of Red Betel Leaf (*Piper betle* Var. *Rubrum*) Extract towards the Healing Time of Incision Wound Infected by *Staphylococcus aureus* on White Rats, Thesis, Faculty of Veterinary Medicine, Universitas Airlangga, Surabaya, 2012.
- [8] M.I. Gill, F.A. Tomas-Barberan and B. Hess-Pierce, Antioxidant activity of pomegranate juice and its relationship with phenolic composition and processing, J. Agric. Food. Chem. 488 (2000) 4581-4589.
- [9] N.P. Seeram, L.S. Adam, S.M. Hanning, Y. Niu, Y. Zhang, M.G. Nair and D. Heber, In vitro antiproliferative, apoptotic and antioxidant activities of punicalagin, ellagic



- acid and a total pomegranate tannin extract are enhanced in combination with other polyphenols as found in pomegranate juice, *J. Nutr. Biochem.* 16 (2005) 360-367.
- [10] N. Suzuki, A. Masamune, K. Kikuta, T. Watanabe, K. Satoh and T. Shimosegawa, Ellagic Acid Inhibits Pancreatic Fibrosis in Male Wistar Bonn/Kobori Rats. *Dig. Dis. Sci.* 54 (2009) 802-810.
- [11] W. M. Yuniarti, Antifibrosis Effect of Pomegranate Extract (*Punica granatum L.*) on Liver Fibrosis, Dissertation, Universitas Airlangga, Surabaya, 2012.
- [12] A. Asali, Introduction of Veterinary Surgical Science, Faculty of Veterinary Medicine, Universitas Airlangga, Surabaya, 1993.
- [13] A. Wandari, Pengaruh Pemberian Ellagic Acid Secara Topikal Terhadap Proses Kesembuhan Luka Insisi Pada Tikus Putih (*Rattus norvegicus*) yang Diinfeksi *Staphylococcus aureus*, Skripsi, Universitas Airlangga, Surabaya, 2013.
- [14] H. Akbari, M.J. Fatemi, M. Iranpour, A. Khodarahmi, M. Baghaee, M.S., Pedram, S. Saleh and S. Araghi, The Healing Effects of Nettle Extract on Second Degree Burn Wounds, *WJPS.* 4.1. (2015) 23-28.
- [15] S. Nayak, P. Nalabothu, S. Sandiford, V. Bhogadi and A. Adogwa. Evaluation of wound healing activity of *Allamanda cathartica L.* and *Laurus nobilis L.* extracts on rats, *BMC Complementary and Alternative Medicine.* 6 (2006) 12.
- [16] M.M. Al-Obaidi, F.H. Al-Bayat, R. Al Batran, P. Hassandarvich and E. Rouhollahi, Protective effect of ellagic acid on healing alveolar bone after tooth extraction in rat: A histological and immunohistochemical study, *Arch. Oral. Bio.* 59 (2014) 987-999.
- [17] P.T. Thang, S. Patrick, L.S. Teik and C.S. Yung, Anti-oxidant effect of the extracts from the leaves of *Chromolaena odorata* on human dermal fibroblasts and epidermal keratinocytes against hydrogen peroxide and hypoxanthine-xanthine oxidase induced damage, *Burns.* 27.4. (2001) 319-327.
- [18] S. Fahimi, M. Abdollahi, S.A. Mortazavi, H. Hajimehdipour, A.H. Abdolghaffari and M.A. Rezvanfar, Wound healing activity of a traditionally used poly herbal product in a burn wound model in rats, *Iran. Red. Crescent. Med. J.* 17 (2015) e19960.
- [19] P.K. Chandran and R. Kuttan, Effect of *Calendula officinalis* Flower Extract on Acute Phase Proteins, Antioxidant Defense Mechanism and Granuloma Formation During thermal Burns, *J. Clin. Biochem. Nutr.* 43.2. (2008) 58-64.
- [20] S.A. Eming, T. Krieg and J.M. Davidson, Inflammation in wound repair: Molecular and cellular mechanisms, *J. Invest. Dermatol.* 127.3. (2007) 514-525.

- [21] K. Annan and P.J. Houghton, Antibacterial, antioxidant and fibroblast growth stimulation of aqueous extracts of *Ficus asperifolia* Miq. and *Gossypium arboreum* L., wound healing plants of Ghana, *J. Ethnopharmacol.* 119.1. (2008) 141-144.
- [22] P. Kumari, P. Yadav, P.R. Verma, S. Kumar and A. Arya, A review on wound healing properties of Indian medicinal plants, *Ind. J. Fund. Appl. Life Sci.* 3.1 (2013) 220-232.
- [23] E. Rivera-Acre, M.A. Chavez-Soto, A. Herrera-Arellano, S. Arzate, J. Aguero and I.A. Feria-Romero, Therapeutic effectiveness of a *Mimosa tenuiflora* cortex extract in venous leg ulceration treatment, *J. Ethnopharmacol.* 109.3. (2007) 523-528.
- [24] F.A. Mendoca, J.R. Passarani Junior, M.A. Esquisatto, J.S. Mendoca, C.C. Franchini and G.M. Santos, Effects of the application of *Aloe vera* (L.) and microcurrent on the healing wounds surgically induced in Wistar rats, *Acta. Cir. Bras.* 24.2. (2009) 150-155.
- [25] A. Li, Y. Zhang, L. Lao, J. Xin, K. Ren and B.M. Berman, Serotonin Receptor 2A/C is Involved in Electroacupuncture Inhibition of Pain in an Osteoarthritis Rat Model, *Evid. Based. Complement. Alternat. Med.* (2011) 619-650.