

Conference Paper

Features of the Manifestation of Marek's Disease in Poultry Farms of the Rostov Region, Russian Federation

Timur Tambiev¹, Arthur Tazayan¹, Vladimir Fedorov¹, Yuri Gak¹, Tatyana Derezhina², and David Avetisyan¹

¹Federal State Budgetary Educational Institution of Higher Education Don State Agrarian University, Persianovski, Russian Federation

²Federal State Budgetary Educational Institution of Higher Education Don State Technical University, Rostov-on-Don, Russian Federation

ORCID:

Timur Tambiev: <http://orcid.org/0000-0003-1561-231X>

Arthur Tazayan: <http://orcid.org/0000-0002-3476-6421>

David Avetisyan: <http://orcid.org/0000-0002-1957-3138>

Abstract

The authors carried out monitoring studies to examine the epizootic process features and the manifestation of clinical signs and pathological changes in Marek's disease in various poultry farms in the Rostov region. The disease was most often in chickens aged 1.5 to 6 months. Two forms of the disease were registered: classical (nervous) - 63.3% of cases, and tumor (visceral) - 36.7% of cases. There was an unequal manifestation of symptoms of the disease, because of the different state of natural resistance and immunological reactivity of sick birds. The main clinical signs of Marek's disease in chickens included: oppression; loss of appetite; development of paresis and paralysis; violation of movement coordination; cachexia; anemic crest, earrings and visible mucous membranes; change in the shape and constriction of the pupil; depigmentation of the iris of the eyes; partial or complete loss of vision; lameness; damage to the feather follicles; and the formation of tumors on the skin. The mortality rate of birds with nervous lesions was 70%. The surviving birds died within 1–2 months from the development of neoplastic changes in the internal organs. The main pathological changes in Marek's disease were thickening and destructive changes in nerve fibers; and neoplastic changes in the parenchymal organs, lungs, intestinal mesentery, gastrointestinal tract, muscle tissue and skin. Most often, the disease was registered in the personal subsidiary plots of citizens. It manifested itself in massive epizootic outbreaks, usually in a nervous form with a high morbidity and mortality. In poultry farms, the disease was recorded extremely rarely. As a rule, it manifested itself in a tumor-like form, in isolated cases among a small percentage of poultry.

Keywords: poultry, chickens, Marek's disease, clinical signs, pathological changes

Corresponding Author:

Timur Tambiev

tim.tambieff-earl@yandex.ru

Published: 5 April 2021

Publishing services provided by
Knowledge E

© Timur Tambiev et al. This article is distributed under the terms of the [Creative Commons Attribution License](#), which permits unrestricted use and redistribution provided that the original author and source are credited.

Selection and Peer-review under the responsibility of the DonAgro Conference Committee.

OPEN ACCESS

1. Introduction

In the poultry farms of the Russian Federation, the situation with Marek's disease remains rather tense. This disease is one of the first among infectious diseases of poultry viral etiology [1]. The disease causes significant losses in the poultry industry, which occur due to an increased mortality of poultry, a decrease in its productivity, and additional costs for preventive and forced antiepidemiological measures [2, 3]. Marek's disease is a highly contagious viral disease of chickens, usually accompanied by the formation of lymphoid tumors in various organs and tissues, lesions of the sciatic nerves, lumbosacral and brachial plexuses, less often the vagus, sympathetic and intercostal nerves, grayish staining of the iris and deformation of the pupil. [4, 5]

The causative agent of the disease belongs to the Herpesviridae family. The virus can be cell-bound and it can be free of cells [6-9]. A distinctive feature of the causative agent of Marek's disease is its ability to persist and evolve in the bird's body for a long time. In this regard, many poultry farms, have are struggling with this disease. New problems constantly arise in the control and diagnosis of this infectious pathology [1, 2, 10].

Treatment for Marek's disease has not been developed and is ineffective. Therefore, the only measure to protect the poultry stock from this infectious pathology is immunization. However, since the virus is constantly mutating, adapting, increasing its virulent properties, there is a need for constant development of new biological products and the need to update the arsenal of available vaccines [1, 3, 11]. It is also important to maintain a high level of biosecurity and a high sanitary condition of poultry facilities [12].

In farms unsuccessful due to Marek's disease, it is important to timely get diagnosis of the disease, to develop and adopt new effective control measures and to fight against this infectious pathology. However, there are some difficulties in diagnosing the disease, since the it is characterized by a wide variety of both clinical signs and pathological changes [1, 13]. For accurate diagnosis, it is necessary to conduct additional serological, molecular genetics and virological studies in the laboratory, which is a rather costly measure for poultry owners [2, 14, 15].

Considering the relevance and significance of Marek's disease for modern poultry farming, the following research goal was chosen - to study the features of the manifestation of infection in poultry farms in the Rostov region. To achieve this goal, the following research tasks were set: to study the features of the epizootic process, the manifestation of clinical signs and pathological changes in Marek's disease.

2. Methods and Equipment

The studies were carried out in 2018–2020. The work was carried out in poultry farms of the Rostov region, engaged in breeding and raising chickens, as well as at the Department of Parasitology, Veterinary and Sanitary Expertise and Epizootology of the Don State Agrarian University.

Marek's disease was diagnosed in a complex manner. The preliminary diagnosis was made based on the analysis of epizootological data, clinical signs and pathological changes. To confirm the diagnosis, the bodies of fallen and forcibly killed birds were sent to the state institution of the Rostov region Rostov Regional Veterinary Laboratory for laboratory research.

When making an epizootic diagnosis according to the Methodological Guidelines for Epizootic Research (1987) and other more modern methods, the authors carried out a retrospective epizootic analysis of the source of the infectious agent, mechanisms and routes of its transmission, predisposing factors, extensive and intensive epizootic indicators.

Clinical examination of the animals was carried out according to the generally accepted scheme. The authors used one of the general research methods, examination and palpation. At the same time, the authors determined duration of the disease, severity of the course, percentage of morbidity and mortality. A total of 980 sick birds were clinically examined during the work.

Pathological diagnostics was carried out according to generally accepted methods. The description of organs and tissues was carried out according to the scheme proposed by professor V.P. Voronyansky (1993). During the research period, 90 chickens were dissected, including those who died and were forcedly killed for diagnostic purposes.

3. Results

The clinical manifestation of the disease was not the same, which depended primarily on the state of natural resistance, immunological status and age of the sick bird. The disease most often occurred in chickens aged from 1.5 to 6 months. In the process of performing the work, sick bird showed the following symptoms of the disease (Table 1):

In 94% of cases, sick bird was inactive and refused to take feed, the plumage was ruffled. In 86.7% of chickens, nervous phenomena characteristic of Marek's disease was noted due to damage to the central and peripheral nervous systems. These phenomena

were characterized by a variety of manifested symptoms, depending on which nerves were affected. Paralysis of the legs, wings, tail, neck and goiter was noted. Pullet chickens often had a soporous state in which the bird was in a standing position, with the neck extended forward and tilted towards the ground (Figure a). Sometimes the neck was bent and turned around its axis. As a result, the bird threw its head on its side or on its back. Some chickens, due to paralysis, lay down on the keel, while the limbs of the bird parted in different directions. The movement of such birds became impossible (Figure 1b)

TABLE 1: Clinical manifestation of Marek’s disease in chickens in poultry farms in the Rostov region.

Clinical signs	Number of chickens	
	heads	%
Anemic crest, earrings, visible mucous membranes	699	71,3
Cachexia	801	81,7
Nervous phenomena	852	86,9
Eye lesions	544	55,5
Diarrhea	367	37,4
Damage to feather follicles and skin	309	31,5
Oppression, refusal to feed	921	94,0
Lameness	272	27,8
Total underwent clinical research	980	100



a



b

Figure 1: Nervous phenomena in Marek’s disease: neck paralysis (a), limb paralysis (b).

As a rule, paralysis of limbs was asymmetrical. Sometimes one limb was struck, which the chickens pulled forward with twisted fingers or dragged it along the ground. In some chickens, paralysis was insignificant. In 27.8% of cases only lameness was noted due to damage to the nerves of the limbs. Due to the inability to get to the feed with a paralyzed bird, due to refusal to eat, as well as metabolic disorders due to illness, 81.7%

of chickens were severely exhausted. In 71.3% of chickens, pallor of the crest and catkins was noted, as well as anemicity of visible mucous membranes.

In 55.5% of cases, the authors noted eye lesions which are characteristic of Marek's disease. In sick chickens, there was a change in the shape and constriction of the pupil, staining of the iris of gray color (gray-eyed). The zenith was often narrowed and took an irregular shape (Figure 2). In chickens with ocular lesions, there often was partial or complete vision loss.

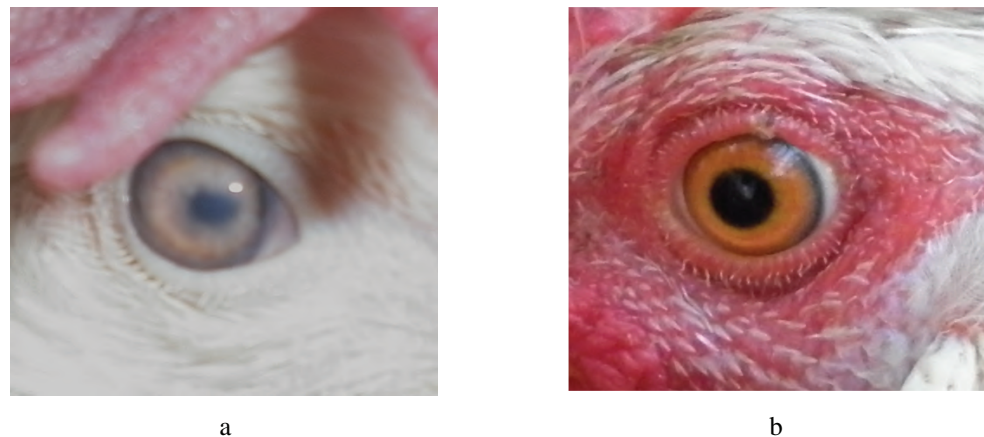


Figure 2: Eye lesions in Marek's disease: sick chicken eye (a), normal chicken eye (b).

Due to damage to the gastrointestinal tract and digestive organs, diarrhea was noted in 37.4% of chickens. As a rule, the droppings were liquid, offensive, greenish-white in color.

The mortality rate of birds with nervous lesions was high and reached 70%. In the rest of the chickens, the nervous phenomena disappeared. However, such seemingly recovered birds, at first glance, still died within 1-2 months from neoplastic changes in their body.

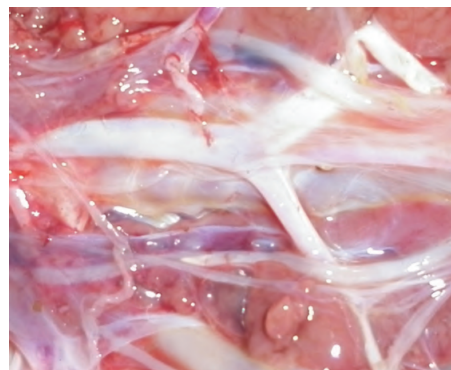In 31.5% of cases, chickens, especially meat breeds, had a cutaneous form of Marek's disease damaging feather follicles and causing skin tumors.

The authors performed the autopsy of 90 chickens during the study. While performing the autopsy of dead birds, the following pathological changes were noted (Table 2).

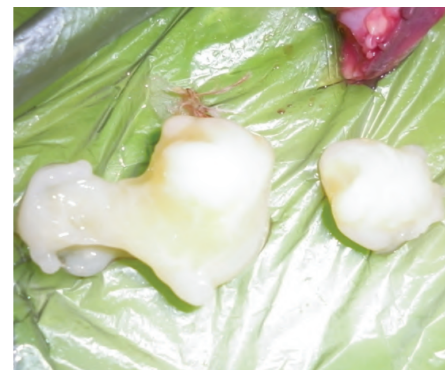The bodies of the dead bird were severely emaciated. In 63.3% of opened chickens, there was diffuse or focal thickening of the nerve trunks and plexuses. Single or multiple tumors of various sizes were found on the nerves. The characteristic changes were observed in the sciatic nerves. They were enlarged 1.5–3 times and softened in places (Figure 3 a). In some chickens, necropsy revealed tumor-like sebaceous formations of various configurations and sizes (Figure 3 b).

TABLE 2: Pathological changes in Marek's disease in chickens in poultry farms in the Rostov region.

Pathological changes	Number of chickens	
	heads	%
Thickening of the sciatic and other nerves	57	63,3
Neoplastic changes in the glandular stomach	24	26,7
Neoplastic changes in the intestine and mesentery	18	20,0
Neoplastic changes in the spleen	33	36,7
Neoplastic changes in the ovaries	27	30,0
Neoplastic changes in the liver	30	33,3
Neoplastic changes in the heart	21	23,3
Neoplastic changes in the kidneys	30	33,3
Neoplastic changes in skeletal muscles	15	16,7
Neoplastic changes in the skin	21	23,3
Follicular hyperplasia	27	30,0
Neoplastic changes in the lungs	12	13,3
In total, underwent pathological examination	90	100



a



b

Figure 3: Pathological changes in Marek's disease: thickening of the sciatic nerve (a), tumor-like formations (b).

Neoplastic changes were found in various internal organs (Figure 4): spleen - 36.7% of cases; liver and kidneys - 33.3%; ovaries - 30.0%; glandular stomach - 26.7%; heart muscle - 23.3%; the intestinal tract and on the intestinal mesentery - 20%; in lungs - 13.3%.

On the skin, in 30% of cases, epithelial hyperplasia was found on the feather follicles in the form of whitish nodules (Figure 5 a). Feather follicles often fused together, taking the form of brown scabs. Scabby, dense, irregularly shaped skin growths occurred in 23.3% of chickens (Figure 5b).

Least often, neoplastic changes were found in skeletal muscles (16.7% of cases). They were most often found in the superficial pectoral muscles as whitish stripes.

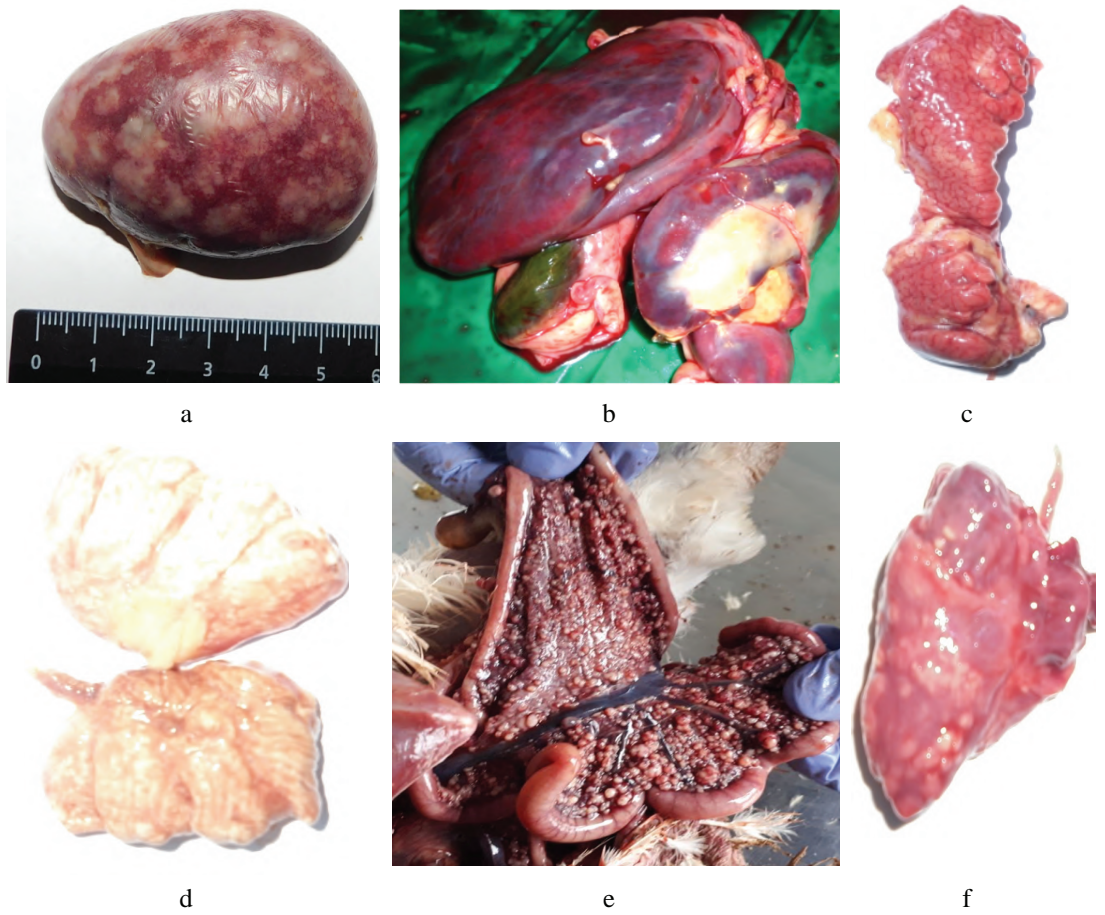


Figure 4: Neoplastic changes in internal organs in Marek's disease: in spleen (a), liver (b), kidneys (c), lungs (d), intestinal mesentery (e), heart (f).

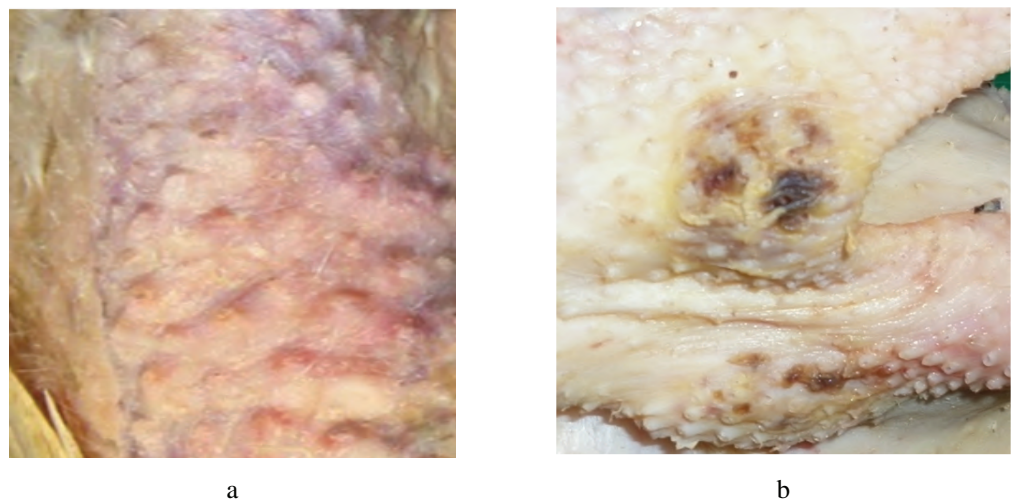


Figure 5: Skin lesions in Marek's disease: hyperplasia of feather follicles (a), tumor-like formations on the skin (b).

4. Discussion

An analysis of the monitoring studies showed that the disease in poultry farms in the Rostov region occurs in two forms: classical (nervous) - 63.3% of cases and tumor (visceral) - 36.7% of cases. At the same time, unequal manifestation of indicators of the epizootic process and clinical signs of the disease was noted in different farms. This circumstance is most likely due to the different state of natural resistance and immunological reactivity of sick birds.

Most often the disease was registered in personal subsidiary plots of citizens. It occurred in the form of massive epizootic outbreaks, usually in a nervous condition with a high morbidity and mortality. This circumstance is explained by the fact that poultry owners in the private sector often neglect to carry out preventive antiepidemiological measures. As a rule, in all personal subsidiary plots where outbreaks of Marek's disease were recorded, there is a high stocking density of chickens, unsatisfactory indoor microclimate parameters and unsanitary conditions of poultry. At the same time, the vaccination of poultry against Marek's disease in such farms was not carried out. Disinfection, as an integral part of the technological cycle, was carried out extremely rarely or was absent altogether.

In industrial enterprises, the disease was recorded extremely rarely. As a rule, it manifested itself in a tumor-like form in the form of isolated cases in a small percentage of the poultry population. This is because large poultry farms have a high level of biological protection of enterprises and mandatory immunization of chickens against Marek's disease is carried out. Isolated cases of the disease are explained by the fact that not all birds develop sufficiently intense immunity after vaccination, which is necessary to maintain the epizootic well-being of farms.

5. Conclusion

With Marek's disease in chickens, there is an unequal manifestation of clinical and pathological signs, which happens due to the different states of natural resistance and immunological reactivity of sick birds.

In the poultry farms of the Rostov region, two forms of the disease are recorded: classical (nervous) - 63.3% and tumor-like (visceral) - 36.7%.

Marek's disease is most seen in chickens between 1.5 and 6 months of age. The mortality of birds with nervous lesions is 70%, the surviving bird dies within 1–2 months from neoplastic changes in the internal organs.

The main clinical signs of Marek's disease in chickens are: oppression; loss of appetite; paresis; paralysis; violation of coordination of movement; cachexia; anemic crest, earrings and visible mucous membranes; change in the shape and constriction of the pupil; depigmentation of the iris of the eyes; partial or complete loss of vision; lameness; damage to feather follicles and the formation of tumors on the skin.

The main pathological changes are thickening and destructive changes in nerve fibers; neoplastic changes in the parenchymal organs, lungs, intestinal mesentery, gastrointestinal tract, muscle tissue and skin.

Funding

The studies were carried out at the expense of funding the state order of the Ministry of Agriculture of the Russian Federation in the framework of research work on the topic "Standard regulations on the state laboratory of veterinary and sanitary examination".

Acknowledgement

The authors would like to thank the administration of the Don State Agrarian University for their support in conducting this study. They are also grateful to all the reviewers who made valuable contributions to the work on the manuscript and helped in its completion.

Conflict of Interest

The authors have no conflict of interest to declare.

References

- [1] Nuraliyev, Y. R. and Kochish, I. I. (2017). Marek's Disease in the Infectious Agent Reservoir of Poultry Industry – Household Farms. *Bulletin of Omsk State Agrarian University*, vol. 4, pp. 162–169.
- [2] Bessarabov, B. F., et al. (2007). *Infectious Diseases of Animals*. Moscow: Koloss.
- [3] Payne, L. N. and Venugopal, K. (2000). Neoplastic Disease: Marek's Disease, Avian Leukosis and Reticuloendotheliosis. *Revue Scientifique et Technique*, vol. 19, pp. 544–564.
- [4] Bakulin, V. A. (2006). *Bird Diseases*. St. Petersburg: Publisher Bakulin V. A.

- [5] Kulyashbekova, S. K., Borisov, A. V. and Drygin, V. V. (2008). *Marek's Disease*. Vladimir: Transit-X.
- [6] Dzhulardov, G. V. (2009). Biological Properties of Natural Isolators of the Marek Disease Virus Circulating in the Russian Federation. (PhD thesis, D.I. Ivanovsky Research Institute of Virology Russian Academy of Sciences, 2009).
- [7] Kennedy, D. A., *et al.* (2017). Industry-Wide Surveillance of Marek's Disease Virus on Commercial Poultry Farms. *Aviandiseases*, vol. 61, pp. 153-164.
- [8] Venugopal, K. (2000). Marek's Disease: An Update on Oncogenic Mechanisms and Control. *Research in Veterinary Science*, vol. 69, pp. 17–23.
- [9] Heidari, M., *et al.* (2016). Marek's Disease Virus Immunosuppression Alters Host Cellular Responses and Immune Gene Expression in the Skin of Infected Chickens. *Veterinary Immunology and Immunopathology*, vol. 180, pp. 21–28.
- [10] Kurnenkova, E. V. and Kulyashbekova, S. K. (2008). Determination of the Marek's Disease Virus Infectious Activity. *Proceedings of the Federal Centre for Animal Health*, vol. 6, pp. 300–306.
- [11] Kulyashbekova, S. K. (2008). Peculiarities of Marek's Disease Vaccine Technology. *Proceedings of the Federal Centre for Animal Health*, vol. 6, pp. 477–498.
- [12] Tambiev, T. S., Garinina, E. R. and Filipisky, O. I. (2019). Disinfection of External Objects in Broiler Poultry. *International Research Journal*, vol. 11-1, pp. 149–152.
- [13] Jarosinski, K. W., *et al.* (2006). Marek's Disease Virus: Lytic Replication, Oncogenesis and Control. *Expert Rev Vaccines*, vol. 5, pp. 761–772.
- [14] Afonyushkin, V., Yushkov, Y. and Gorodov, V. (2005). Results of using the Computer Modeling for Developing a PCR-System Being Optimal for Screening Technologies of Marek's Disease Control. *Siberian Herald of Agricultural Science*, vol. 2, pp. 69–74.
- [15] Glisson, J. R., *et al.* (2008). *A Laboratory Manual for the Isolation, Identification and Characterization of Avian Pathogens* (5th ed.). Athens: American Association of Avian Pathologists.