

Conference Paper

Anomalies and Pathology in the Bones of the Late Cenozoic Ectothermic Tetrapods

V.Yu. Ratnikov

Voronezh State University, 394018 Voronezh, University sq., 1

Abstract

Anomalies and pathologies can be observed in fossil animals. Among these pathologies are tumors, callus in fractures and the underdevelopment of skeleton elements. Anomalies often occur in the spine and are represented by the fusion of the vertebrae, variations in the joints and the deformation of skeletal elements. Sometimes anomalies and pathology combined in a single element of the skeleton. These anomalies and pathologies may not always be recognized in fossil material, especially if it is small in size. In this case, anomalies can be described as new taxa.

Keywords: fossil bones, pathologies, anomalies.

Corresponding Author:

V.Yu. Ratnikov
 vratnik@yandex.ru

Received: 23 January 2018

Accepted: 20 April 2018

Published: 3 May 2018

Publishing services provided by
 Knowledge E

© V.Yu. Ratnikov. This article is distributed under the terms of the [Creative Commons](#)

[Attribution License](#), which permits unrestricted use and redistribution provided that the original author and source are credited.

Selection and Peer-review under the responsibility of the Amphibian and Reptiles Anomalies and Pathology Conference Committee.

1. Introduction

Morphological abnormalities, including skeletal ones, are a common phenomenon. Deviations in the spines of anura are observed most often. They were registered in about 15% of all investigated individuals of common frogs, and this indicator in some populations reached 21.9% [2]. These anomalies can be found in fossil bones, too. The presence of pathologies caused by trauma and disease is also expected. Below I will give an overview of the anomalies and pathologies discovered in my fossil collections.

2. Overview

Anomalies and pathology in fossil materials are not rare. Apparent samples have been found in all major locations of tailless amphibians containing 1000 or more bones, such as Voroncha [1], Rudny, Zmeyovka-2 [3] and Tologoi [4]. However, there are no clear boundaries between the three concepts: norm, abnormality and pathology [2]. It is not always possible to say what is represented in the observable exemplars.

 OPEN ACCESS




Figure 1: Pathology and anomalies in the bones of anurans: a-c - tumors at *Rana temporaria* bones, Voroncha: a-b - scapula, inner and outer views; c - radioulna; d-f - fractures of *Rana temporaria* radioulna, Rudny: d - with displacement, e-f - without displacement, from two sides; g-h - underdevelopment of *Rana temporaria* ilium, Voroncha, inner and outer views; i - biconvex vertebra of frog, Voroncha, ventral view; j - opisthocoelous vertebra of toad, Voroncha, ventral view; k - fusion of anterior frog vertebrae, Voroncha, dorsal view; l-m - fusion of presacral frog vertebrae, Voroncha, ventral and dorsal views; n-o - transversal processes at frog urostyles, Voroncha, lateral views.

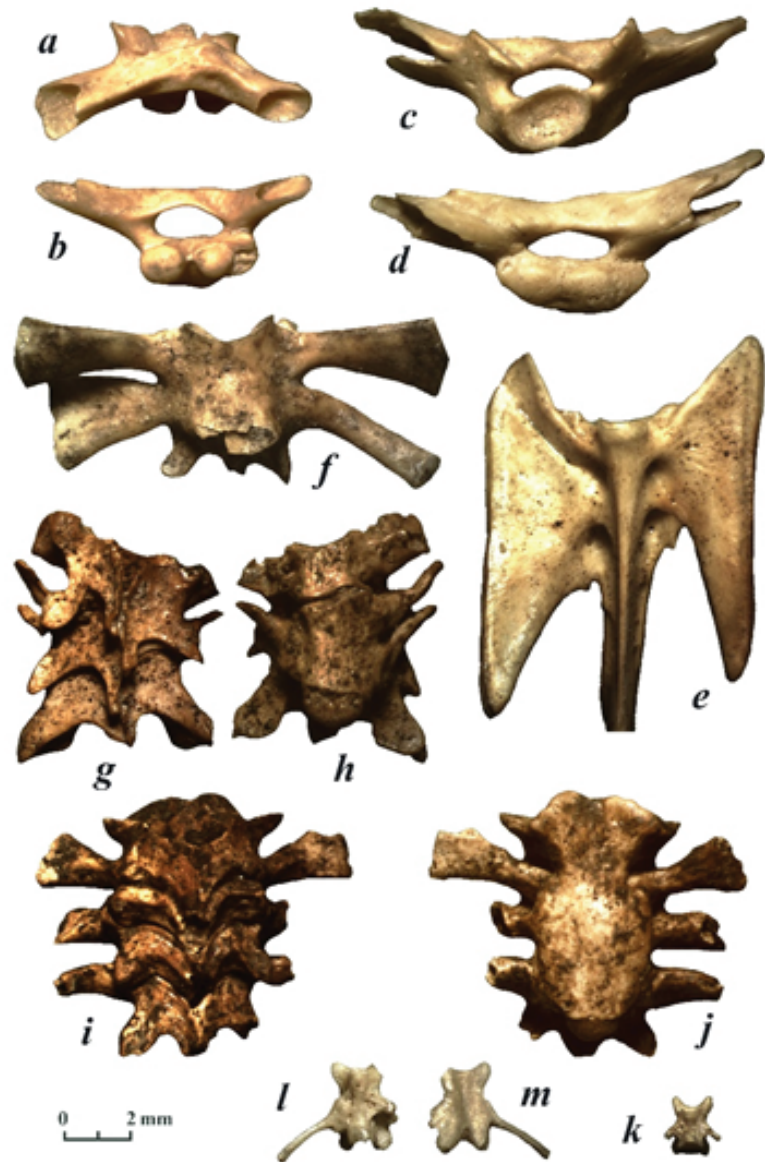


Figure 2: Anomalies in the bones of amphibians: a-b – deformation of frog sacrum, Voroncha, dorsal and posterior views; c-d – deformation of toad sacrum, Voroncha, anterior and posterior views; e – deformation of spadefoot sacrococcygis, Chirkovo, ventral view; f – combination of vertebral fusion with deformation of diapophyses form, Tepke, ventral view; g-h – combination of vertebral fusion with deformation of their form, Zmeyovka-2, dorsal and ventral views; i-j – combination of vertebral fusion with tumor, Zmeyovka-2, dorsal and ventral views; k - amphicoelous trunk vertebra of *Triturus cristatus*; l-m - fused rib and asymmetry in vertebra of *Lissotriton vulgaris*.

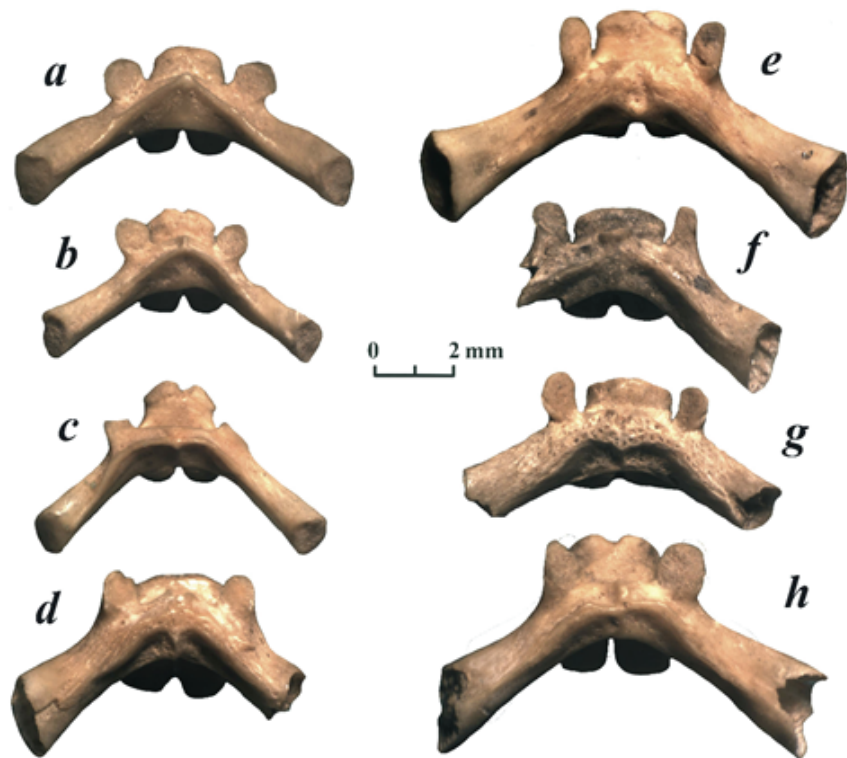


Figure 3: Variability of *Rana temporaria* sacrum bones from the Voroncha locality, dorsal views.

Obvious pathologies observed on fossil bones are tumors on various skeletal elements and their various parts, healed fractures and hypoplasia of bones (Fig. 1 a-h). Anomalies in the spine include the unusual shape of the articular surfaces of the vertebral bodies, fusion of the bodies and neural arcs of the vertebrae, the presence of transverse processes on urostyle (Fig. 1 i-o) and the deformation of skeletal elements (Fig. 2 a-e). Sometimes there are combinations of different abnormalities (Fig. 2 f-h) or abnormalities with pathologies (Fig. 2 i-j).

Although there are far few findings of tailed amphibians compared to tailless ones, there are also deformities among them (Fig. 2 k-m).

I would like to particularly discuss the cases when it is not clear whether there is an anomaly in front of us or not. Fig. 3 shows the variability of the transverse crest shape in the sacrum of common frogs. The form of the transverse process in Figure 3e is not inherent to the common frog, and we can talk about the abnormality only because this vertebra is among the mass of normal vertebrae. However, if we found only this vertebra, it would be possible to describe a new species or genus. Nevertheless, bones with unusual morphology can occur in a few collections, too. A paleontologist must decide what status to give the unusual morphology of bones: you can describe

it as a new species or consider it an abnormal variant. Usually, we attribute more ancient findings to extinct species, while younger ones are more often considered as anomalies. The nature of this phenomenon is the same: the formation of new species begins with the appearance of the abnormal morphology of the ancestor.

3. Conclusion

Perhaps parts of the described new fossil species represent only anomalies in the morphology of other species. Unfortunately, it is very difficult to distinguish them. It is necessary to involve all colleagues to resolve such issues. For this, descriptions and images of all unusual remains must be published to attract the attention of specialists.

References

- [1] Ivanov DL, Ratnikov VYu, Motuzko AN: Paleoherpetologicheskiye issledovaniya v Belarusi: rekonstruktsiya uslovii formirovaniya mestonakhozhdeniya Voroncha. Vestnik BGU, Seriya 2: Chemistry, Biology, Geography. 2014, № 3: 71-76 [in Russian].
- [2] Kovalenko EE: The anomalies of vertebrate column in Anura. St Peterburg: Publishing house of St. Petersburg University; 1992 [in Russian].
- [3] Ratnikov, VYu: Verkhnechetvertichnye gerpetofauny Belgorodskoy oblasti. Paleont. Zh. 1988, № 3: 119-122 [in Russian].
- [4] Ratnikov, VYu: Tailless amphibians and landscape settings of the late Cenozoic in Western Transbaikalia. Russian Geology and Geophysics. 1997, 38, № 9: 1493-1500.