

Conference Paper

Teratogenic Effect of Congenital Toxoplasmosis in Chicken Embryo

Lucia Tri Suwanti¹, Mufasirin², Hani Plumeriastuti², and Erma Safitri³¹Veterinary Parasitology Department of Veterinary Medicine Faculty Surabaya, 60115, Indonesia²Veterinary Pathology Department of Veterinary Medicine Faculty, Surabaya, 60115, Indonesia³Veterinary Reproduction Department of Veterinary Medicine Faculty, Surabaya, 60115, Indonesia

Abstract

This research is designed to observe the teratogenic effect of *Toxoplasma gondii* infection in chick embryos, based on the number of somites, embryo length and the development of embryonic brain vesicles. Methods in the research: Chicken eggs were infected with 1×10^3 tachyzoites of *T. gondii*. The eggs were incubated in eggs hatching box. Observation of somite performed on embryonated eggs 24 hours after incubation and the embryonic development of vesicles performed 72 hours after incubation then the length of each embryo were measured. Results: Revealed that there was a significant difference in the number of somites ($p < 0.1$), *T. gondii* infection reduced the number of somites. While in the number of brain vesicles in 3 - days old chicken embryos, although there was no significant difference, the size declining emerged. The length of the embryos both at 24 or 72 hours old showed that *T. gondii* infection reduced the length ($p < 0.1$). Conclusions: *T. gondii* infection influences the development of chicken embryos in the declining of length and the decreasing of somite embryo number.

Keywords: IGF-I crossbreed mare serum pregnant; Follicle; Mus musculus.

1. Introduction

Toxoplasmosis is a zoonotic disease that caused by the parasitic protozoan *Toxoplasma gondii* [1-4]. Humans, livestock and poultry were infected by sporulating oocysts that pollute the environment [5-6]. A human can also be infected by eating undercooked meat [7-8]. In pregnant mammals, both livestock and human, *T. gondii* infection can be transmitted transplacentally [9] and may risk the fetus to get fetal absorption, abortion, stillbirth, infant death and congenital abnormalities born weak, depending on the time of gestation getting an infection [10-12]. *T. gondii* infection, in livestock, is also given rise to problems such as fetal pathology and abortion [12]. *T. gondii* infection is a major cause of abortion goats and sheep in several countries including Australia

Corresponding Author:

Lucia Tri Suwanti

Received: 03 October 2017

Accepted: 10 October 2017

Published: 29 November 2017

Publishing services provided
by Knowledge E

© Lucia Tri Suwanti et al. This article is distributed under the terms of the [Creative Commons Attribution License](#), which permits unrestricted use and redistribution provided that the original author and source are credited.

Selection and Peer-review under the responsibility of the VMIC Conference Committee.

 OPEN ACCESS

and the United States. The frequency of occurrence of abortion and fetal death in sheep infected with *T. gondii* is quite high [13-14]. Studies on the incidence of toxoplasmosis in chickens and chicken eggs have been done by several researchers. The study includes serological and parasitological study and the results of these studies indicate the incidence of toxoplasmosis in chickens and eggs is quite high [15-17]

The risk of infection due to chicken embryos in eggs rarely have been reported. The aim of this research is to reveal the teratogenic effects of *T. gondii* infection in chicken embryos, based on the number of somites, the development of the embryonic brain vesicles and length of the embryo. It is expected that this study can be used as a research model of *T. gondii* infection teratogenic effects in mammals, including human embryos

2. Materials and methods

Forty chicken eggs were divided into two groups. The first groups as a control and the other infected with *T. gondii*. Isolates of *T. gondii* was RH strain. Infection procedures appropriated with [18-19]. Infection dose was 1×10^3 tachyzoites. tachyzoites injected into chorioallantois and then closed with paraffin and masking tape. After infection, all of the eggs were incubated in hatching box.

Teratogenic effects based on embryonic development, include: the number of somites in the embryo, the length of embryos and brain vesicle formation Isolation Embryos was done by using whole- mounts [20]. Ten embryonated chicken eggs of each group were observed at 24 hours and then the other at 72 hours after incubation. Embryonated chicken eggs were opened by eggshell peeling.

The egg was dipped in 0.9% saline buffer and simultaneity poured the contents of the egg. The red part in hollow eggs was containing an embryo. Embryonic membranes were cut using a glass slide and embryo was raised and put on the glass. Embryos were observed under a microscope. The embryonic length was measured from the anterior end to the posterior end of the embryo ages 24 and 72 hours after infection, a number of somites were calculated on embryo 24 hours old and the development of embryonic vesicles was done embryonated chicken eggs age of 72 hours.

The number and length of somite chicken embryos were analyzed by t test, while for the development of embryonic vesicles descriptively presented.

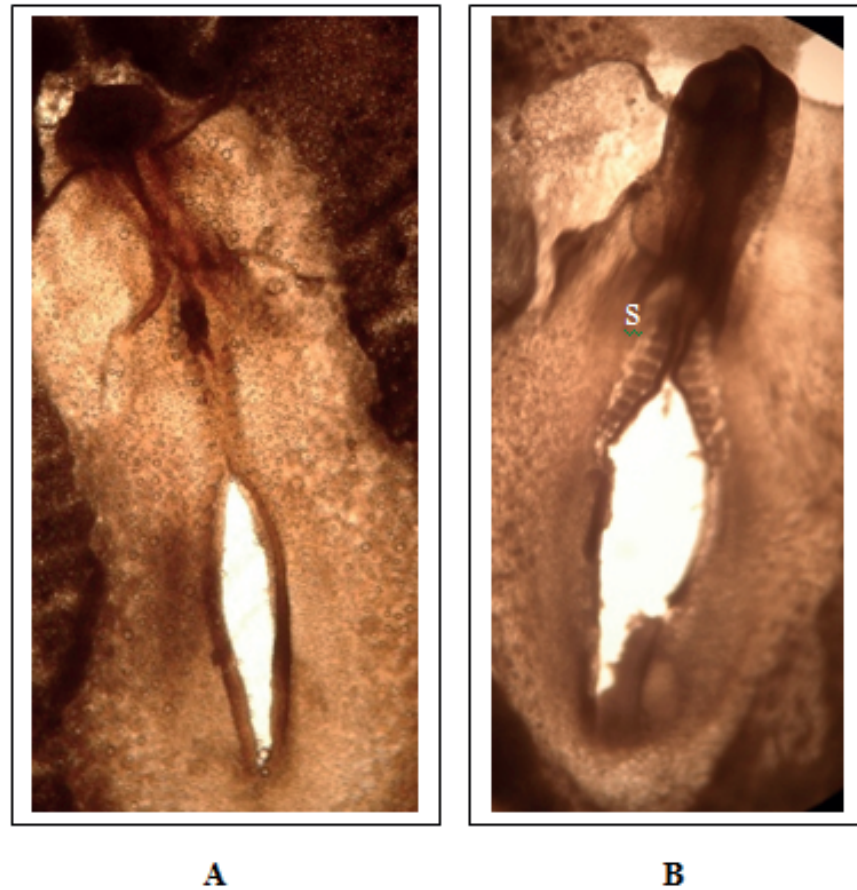


Figure 1: Chicken embryo after 24 hours incubation. **A.** Control . **B.** infected with *T. gondii* S: somite.

3. Results

From the statistical analysis, the number of somites was a significant difference ($p < 0.1$) between chicken embryos infected compared with uninfected. In infected embryos, the number of somites decreased from 12.8 (uninfected) become 9.4 (infected). (Table 1 and Figure 1).

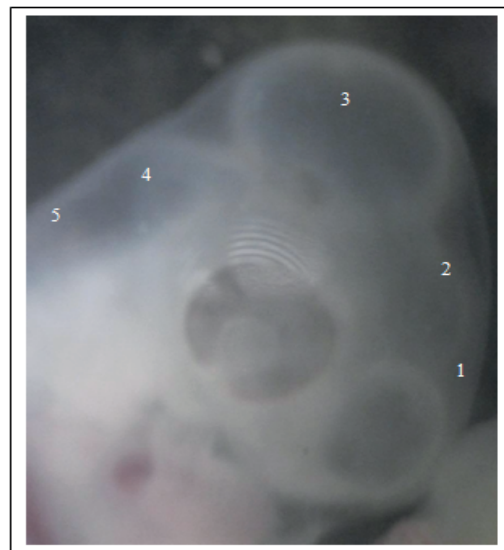
The results of the measurement of the length of the embryo on 24 hours and 72 hours showed that the infection *T. gondii* decrease the length of the embryo. In control groups (uninfected egg) was 0.56 cm and 1.80 cm but in infected eggs were 0.42 cm and 1.12 cm (Tabel 1).

In 72 hours old chicken embryos, both infected and uninfected, all vesicles in the brain are already complete, but brain size in infected group was significantly decreased compared with the control group (Figure 2).

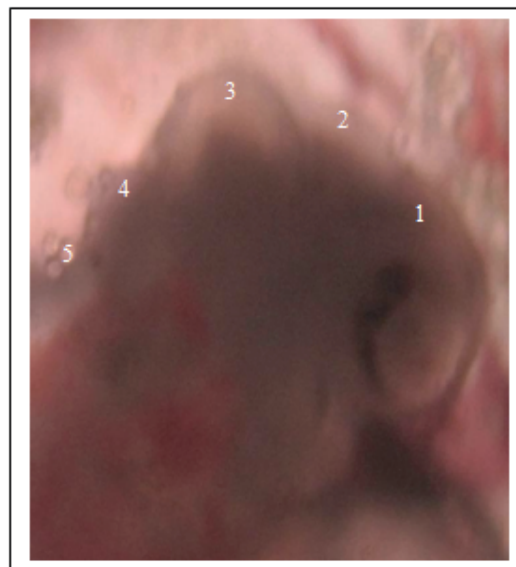
A somite is part of the embryo that will develop into skeletal muscles and skeleton, in the development of somite chick embryo begins to form in 21 hours after incubation

TABLE 1: Mean and Standard Deviation of number of somite and length chicken embryos 24 and 72 hours after incubation.

		number of somite (24 hours after incubation)	length embryo (cm)	
			24 hours after incubation	72 hours after incubation
Treatment	Control	12,80±0,87	0,56±0,05	1,80±0,20
	Infected	9,40±0,55	0,42±0,04	1,12±0,08



A



B

Figure 2: Barin of Chicken embryo after 76 hours incubation. **A.** Control (12,5x) . **B.** infected with *T. gondii* (40x) 1. Telencephalon, 2. Diencephalon, 3. Mesencephalon, 4. Myelencephalon, 5. Metencephalon.

[20]. In this study, observation of the number of somites was done in 24 hours after incubation. In infected group, the number of somites was fewer than an uninfected egg

(Table 1), it indicates that *T. gondii* infection has affected the development of chicken embryos since the first day (24 hours) after infection. This indication is the explanation of the declining of embryos length, both of which lasted for one day or three-day experience also decrease (Table 1).

Moreover, since skeletal muscle is a potential somite and skeletal, the somite number decreases when the length of the frame also decreases, consequently decreasing the length of the embryo as well. The decrease in the number and length of somite embryo is probably also the explanation of the results of previous research, which says that *T. gondii* infection causes a decrease in fetal mice [21].

The decreasing of the number of somite and length chick embryos may caused by Toxopain-1. Toxopain-1 is a member of a family of cysteine proteinase that plays a role in the pathogenesis of *T.gondii* infection [18]. This protein is a product rhoptry of *T. gondii* and it is released during *T. gondii* penetrate the host cell membrane to survive and multiply. Toxopain-1 plays a role in the pathogenesis of congenital toxoplasmosis, the research found that Toxopain-1 inhibited the development of chicken embryo manifested by weight of embryos and organs of the embryo and the embryo occurs more severe organ damage [18].

In the development of the chicken embryonic brain, differentiation has been perfect at 72 hours after incubation marked five vesicle formation which are: Telencephalon, Diencephalon, mesencephalon, Mielenchephalon, and Metecephalon. During the process of embryonic brain development, it is very susceptible to the presence of the teratogen agents [20].

Based on the number of brain vesicles of 3-day old chicken embryos, there was not the significant difference between groups of infected and uninfected eggs. The number of brain vesicles from both groups is complete, there are 5 vesicles emerged. It is shown that *T. gondii* infection does not affect against the differentiation of the brain. But judging from its structure, *T. gondii* infection may cause the decreasing of the brain size (Figure 2).

From the results, it can be concluded that there was no effect of *T. gondii* infection in the formation of brain vesicles and it can not be used as an occurrence marker of teratogenic effects of infectious agents. Teratogenic effects on embryonic development has to be thoroughly observed in it's all parameters which are somite number, the length of the embryo, embryo weight and death embryo.

Toxoplasma gondii infection affects the development of the chick embryo by the decrease in the number and length of somite embryos and Toxoplasmosis infection had no effect on chicken embryonic brain vesicle formation.

References

- [1] Astrid M. Tentera, Anja R. Heckerotha, and Louis M. Weissb. *Toxoplasma gondii*: from animals to humans. *Int J Parasitol.* 2000 November; 30(12-13): 1217–1258.
- [2] Sonar S. S. and Brahmabhatt M.N. *Toxoplasmosis: An Important Protozoan Zoonosis.* *Veterinary World Vol.3(9):436-439*
- [3] Francisco Mimica, Claudia Muñoz-Zanzi, Marisa Torres y Oslando Padilla. *Toxoplasmosis, a parasitic zoonoses prevalent in Chile: count and challenges*
- [4] Ahmad S, Tasawar Z. *Toxoplasmosis In Four Caprine Breeds: A Future Risk Of Zoonosis.* *The Journal of Animal & Plant Sciences*, 26(2): 2016, Page: 388-394
- [5] Karen Shapiro* John Largier, Jonna A. K. Mazet, William Bernt, John R. Ell, Ann C. Melli, Patricia A. Conrad. *Surface Properties of Toxoplasma gondii Oocysts and Surrogate Microspheres.* *Applied and Environmental Microbiology*, Feb. 2009, p. 1185–1191
- [6] Emily L Lilly and Caroline D Wortham. *High prevalence of Toxoplasma gondii oocyst shedding in stray and pet cats (Felis catus) in Virginia, United States.* *Lilly and Wortham Parasites & Vectors* 2013, 6:266
- [7] Dubey JP, Hill DE, Jones JL, Hightower HW, Kirkland E, Roberts JM, Marcet PL, Lehmann T, Vianna MCB, Miska K, Sreekumar C, Kwok OCH, Shen SK, and Gamble HR. *Prevalence Of Viable Toxoplasma Gondii In Beef, Chicken, And Pork From Retail Meat Stores In The United States: Risk Assessment To Consumers.* *Journal of Parasitology.* Oct 2005 : Vol. 91, Issue 5, pg(s) 1082- 1093.
- [8] Berger-Schocha E, Herrmann DC, Schares G, Müller N, Bernet D, Gottsteina B, Freya CF. *Prevalence and genotypes of Toxoplasma gondii in feline faeces (oocysts) and meat from sheep, cattle and pigs in Switzerland.* *d. Vet. Parasitol.* 2010(6): 1-8.
- [9] Hill D, Dubey JP. *Toxoplasma gondii: transmission, diagnosis and prevention.* *Clin Microbiol Infect* 2002; 8: 634–640
- [10] Dubey JP, Lindsay DS, and Speer CA. *Structures of Toxoplasma gondii tachyzoites, bradyzoites, and sporozoites and biology and development of tissue cysts.* *J CMR* 1998; 11(2): 267-299
- [11] Weissmann J.. *Presumptive Toxoplasma gondii abortion in sheep.* *J Can Vet* 2003; 44(4): 322-324
- [12] Dubey JP and Jones JL. *Toxoplasma gondii infection in human and animals in the United States.* *Internas. J. Parasitol.* 2010; 38:1257-1278.
- [13] Duncanson P, Terry RS, Smith JE, and Hide G, *High levels of congenital transmission of Toxoplasma gondii in a commercial sheep flock.* *Int J Parasitol.* 2001; 31(14):1699-703

- [14] Rahdar M, Samarbaf-Zadeh AR, Arab L. Evaluating the Prevalence of *Toxoplasma gondii* in Meat and Meat Products in Ahvaz by PCR Method. *Jundishapur J Microbiol.* 2012;5(4):570-573.
- [15] Mufasirin, Suprihati E dan Suwanti LT. Studi Toxoplasmosis pada Telur Ayam Buras Yang Dijual Sebagai Campuran Jamu di Kota Surabaya dan kabupaten Sidoarjo Menggunakan Uji Dot Blot. *J. Penelit. Med Eksakta.* 2003; 4:113-119.
- [16] Mufasirin dan Suwanti LT. Deteksi *Toxoplasma gondii* Pada Telur Ayam Buras Yang Dijual Sebagai Campuran Jamu Di Kota Surabaya Menggunakan Uji Biologis. *Media Kedokteran Hewan.* 2008 24(1); 5-9
- [17] Suwanti LT. Weight Reduction of Fetuses of *Toxoplasma gondii*-infected Mice. *Proceeding International Conference "Animal Health and Human Safety" UPM Malaysia.* 2009, pp 197-200
- [18] Que, XC, Wuderlich A, Joiner KA, and Reed SL. Toxopain-1 is Critical for Infection in a Novel Chicken Embryo Model of Congenital Toxoplasmosis. *IAI.* 2004; 72(5):2915-2921
- [19] Furuta PI, Mineo TWP, Carrasco AOT, Godoy GS, Pinto AA, Machado RZ. Neospora caninum infection in birds: experimental infections in chicken and embryonated eggs. *Parasitology* (2007), 134, 1931-1939
- [20] Luqman, EM, Soenardihardjo BP, dan Mahaputra L. Peranann Choline Esterase (ChE) pada Pembentukan Vesikel Otak Embrio Ayam yang Terpapar Insektisida Karbofuran. *Media Kedokteran Hewan.* 2007; 23(3):145-150
- [21] Suwanti LT, Suprihati E, dan Mufasirin.. Deteksi Kista Jaringan *Toxoplasma gondii* pada beberapa organ ayam. *Lemlit. Unair. Surabaya.* 2003. 1-21